

# The 2021 European Group on Graves' orbitopathy (EUGOGO) clinical practice guidelines for the medical management of Graves' orbitopathy

L Bartalena<sup>1,\*</sup>, G J Kahaly<sup>2,\*</sup>, L Baldeschi<sup>3</sup>, C M Dayan<sup>4</sup>, A Eckstein<sup>5</sup>, C Marcocci<sup>6</sup>, M Marinò<sup>6</sup>, B Vaidya<sup>7</sup> and W M Wiersinga<sup>8</sup> on behalf of EUGOGO<sup>†</sup>

<sup>1</sup>Department of Medicine and Surgery, University of Insubria, Varese, Italy, <sup>2</sup>Department of Medicine I, Johannes Gutenberg-University (JGU) Medical Center, Mainz, Germany, <sup>3</sup>Department of Ophthalmology, Cliniques Universitaires Saint Luc, Catholic University of Louvain, Brussels, Belgium, <sup>4</sup>Thyroid Research Group, Cardiff University School of Medicine, Cardiff, UK, <sup>5</sup>Clinic for Ophthalmology, University Clinic, Essen, Germany, <sup>6</sup>Department of Clinical and Experimental Medicine, University of Pisa, Pisa, Italy, <sup>7</sup>Department of Endocrinology, Royal Devon & Exeter Hospital and University of Exeter Medical School, Exeter, UK, and <sup>8</sup>Amsterdam University Medical Center, Amsterdam, the Netherlands

\*(L Bartalena and G J Kahaly contributed equally to this work and share first authorship)

†(List of EUGOGO members who collaborated for this Guideline is provided in the Acknowledgements section)

Correspondence  
should be addressed  
to G J Kahaly  
**Email**  
gkahaly@uni-mainz.de

## Abstract

Graves' orbitopathy (GO) is the main extrathyroidal manifestation of Graves' disease (GD). Choice of treatment should be based on the assessment of clinical activity and severity of GO. Early referral to specialized centers is fundamental for most patients with GO. Risk factors include smoking, thyroid dysfunction, high serum level of thyrotropin receptor antibodies, radioactive iodine (RAI) treatment, and hypercholesterolemia. In mild and active GO, control of risk factors, local treatments, and selenium (selenium-deficient areas) are usually sufficient; if RAI treatment is selected to manage GD, low-dose oral prednisone prophylaxis is needed, especially if risk factors coexist. For both active moderate-to-severe and sight-threatening GO, antithyroid drugs are preferred when managing Graves' hyperthyroidism. In moderate-to-severe and active GO i.v. glucocorticoids are more effective and better tolerated than oral glucocorticoids. Based on current evidence and efficacy/safety profile, costs and reimbursement, drug availability, long-term effectiveness, and patient choice after extensive counseling, a combination of i.v. methylprednisolone and mycophenolate sodium is recommended as first-line treatment. A cumulative dose of 4.5 g of i.v. methylprednisolone in 12 weekly infusions is the optimal regimen. Alternatively, higher cumulative doses not exceeding 8 g can be used as monotherapy in most severe cases and constant/inconstant diplopia. Second-line treatments for moderate-to-severe and active GO include (a) the second course of i.v. methylprednisolone (7.5 g) subsequent to careful ophthalmic and biochemical evaluation, (b) oral prednisone/prednisolone combined with either cyclosporine or azathioprine; (c) orbital radiotherapy combined with oral or i.v. glucocorticoids, (d) teprotumumab; (e) rituximab and (f) tocilizumab. Sight-threatening GO is treated with several high single doses of i.v. methylprednisolone per week and, if unresponsive, with urgent orbital decompression. Rehabilitative surgery (orbital decompression, squint, and eyelid surgery) is indicated for inactive residual GO manifestations.

*European Journal of  
Endocrinology*  
(2021) **185**, G43–G67

## Introduction

Graves' orbitopathy (GO), also called thyroid eye disease or thyroid-associated orbitopathy, is the major extrathyroidal manifestation of Graves' disease (GD), although it may less frequently occur in patients with chronic autoimmune thyroiditis (1). GO is relatively rare (estimated incidence: 0.54–0.9 cases/100 000/year in men, 2.67–3.3 cases/100 000/year in women) with more commonly mild and non-progressive cases and moderate-to-severe forms accounting for 5–6% of cases only (2, 3). GO has an impact on quality of life (QoL), even within mild disease (4, 5, 6) and poses a significant public health burden, in terms of direct and indirect costs (7). GO is a major therapeutic challenge in its moderate-to-severe forms, often incompletely responsive to available medical treatments. After the publication of the 2016 European Thyroid Association (ETA)/European Group on GO (EUGOGO) guidelines for the management of GO (8), several relevant studies have been published, particularly randomized clinical trials (RCTs) of newer biological agents for the treatment of moderate-to-severe and active GO (1, 9, 10, 11, 12). This prompted the EUGOGO Executive Committee to appoint an *ad hoc* task force committed to updating the guidelines, focusing on the medical management of GO. A synopsis of recommendations is presented in Table 1. Emergency and rehabilitative surgery of GO is briefly discussed, as it will be separately addressed by the ophthalmologist members of EUGOGO.

## Methods

### Literature search

Data acquisition was based on PubMed search strategies, with particular regard to papers published subsequent to the 2016 ETA/EUGOGO guidelines (8). In addition, the list of references of relevant citations and chapters of major textbooks were evaluated for any additional appropriate citation.

### Grading

The GRADE system was used to make recommendations and express the quality of the evidence (13). The task force used the following coding system (a) indicates a strong recommendation and is associated with the phrase 'we recommend', and (b) denotes a weak recommendation and is associated with the phrase 'we suggest'. Evidence grading: ØØØØ denotes very-low quality evidence;

ØØØØ, low quality; ØØØØ, moderate quality; ØØØØ, high quality. The draft was submitted to all members of EUGOGO and commented on by e-mail. All members of the task force unanimously approved the final version and the 32 recommendations. Each EUGOGO site identified 1–2 members to be acknowledged as contributors. Among 48 potential contributors, written permission for being acknowledged was granted by 48 (100%).

## Classification of GO

Treatment decisions are based on clinical activity, severity, and duration of GO (8, 14) as anti-inflammatory/immunosuppressive treatment is significantly less effective after 18 months of disease duration (15) (Recommendation #1).

### Activity

The clinical activity score (CAS) is the best validated scoring system, although it has limitations, such as its binary (yes/no) feature, and should be, therefore, used for assessing activity (16). CAS is composed of seven items: GO is defined as active if CAS is  $\geq 3/7$  (Table 2). A ten-item CAS, including an increase in exophthalmos  $\geq 2$  mm, a decrease of eye movements in any direction of gaze  $\geq 8^\circ$ , and a decrease of visual acuity  $\geq 1$  line on the Snellen chart during a period of 1–3 months, is useful to evaluate recent progression and, therefore, the activity of GO (16). A picture atlas to ensure consistent CAS assessment has been published (17). Other inflammation scores, such as the VISA score (18) may be useful, but an adequate validation is not available. Specific MRI sequences may be useful in quantifying disease activity and predicting response to anti-inflammatory treatment and outcome of GO (19, 20, 21); however, costs and availability substantially limit MRI application in daily practice.

### Severity

The EUGOGO classification into mild, moderate-to-severe, and sight-threatening GO (Table 3) has been validated in clinical and research studies (8, 22) and should, therefore, be used. Other scorings systems, that is, VISA (18), NOSPECS (23, 24), total eye score (25) allow quantification. MRI and CT scans provide information on the amount and distribution of orbital tissue expansion (muscle thickening, fat volume increase, apical crowding). Overall, orbital MRI is indicated in patients with unilateral or strongly

**Table 1** The EUGOGO evidence-based recommendations for the management of Graves' orbitopathy (GO).

Number	Recommendations	Strength of recommendation and level of evidence
1	Assessment Clinical activity and severity of Graves' orbitopathy (GO) should be assessed according to standardized criteria and GO be categorized as active or inactive, and mild, moderate-to-severe, or sight-threatening, and should include evaluation of quality of life (QoL) by the EUGOGO disease-specific GO-QoL questionnaire	1, 0000
2	Specialized centers and risk factors We recommend that primary-care physicians, general practitioners, general internists and specialists should refer patients with overt GO and mild cases at risk to deteriorate (clinically active GO, smokers, severe/unstable hyperthyroidism, high serum thyrotropin receptor antibody (TSHR-Ab) titers), to combined thyroid-eye clinics or specialized centers providing both endocrine and ophthalmic expertise, as this will provide an accurate and timely diagnosis to improve prognosis and QoL	1, 0000
3	Quit smoking Physicians should urge all patients with Graves' hyperthyroidism, irrespective of the presence/absence of GO, to refrain from smoking	1, 0000
4	Thyroid dysfunction Euthyroidism should be promptly restored and stably maintained in all patients with GO	1, 0000
5	Glucocorticoid prophylaxis Oral prednisone/prednisolone prophylaxis should be given to radioactive iodine (RAI)-treated patients at risk of progression or <i>de novo</i> development of GO (smokers, severe/unstable hyperthyroidism, high serum TSHR-Ab). Regimen: high risk: 0.3–0.5 mg/kg/bodyweight as starting dose, tapered, and withdrawn after 3 months; low risk: 0.1–0.2 mg/kg/bodyweight, tapered, and withdrawn after 6 weeks. Patients with longstanding and stably inactive GO can receive RAI without prednisone/prednisolone cover if risk factors for GO progression, particularly smoking and high serum TSHR-Ab titers are absent. Uncontrolled post-RAI hypothyroidism should be avoided.	1, 0000
6	Local treatments All patients with GO should be extensively treated locally with artificial tears at all times in the course of their disease unless corneal exposure requires higher protection than ophthalmic gels or ointment, especially at nighttime	1, 0000
7	Mild GO Mild GO should be treated with local treatments and general measures to control risk factors; a 6-month selenium supplementation should be given to patients with mild and active GO of recent onset, because it improves eye manifestations and QoL and usually prevents GO progression to more severe forms	1, 0000
8	Mild GO If the impact of the disease on the QoL outweighs risks, then low-dose immunomodulatory therapy (active GO) or rehabilitative surgery (inactive GO) is proposed subsequent to extensive counseling and shared decision	2, 0000
9	Counseling and selection of treatment for moderate-to-severe and active GO Extensive counseling is warranted to explain aims and expectations, benefits and risks of different therapies. Selection of treatment relies on evidence-based effectiveness, safety, evaluation of costs, reimbursement by the health system, drug availability, facilities for delivering highly specialized treatments, and personal choice of the informed patient within a shared decision-making process.	1, 0000
10	Cumulative dose of i.v. glucocorticoids The cumulative dose of i.v. glucocorticoids should not exceed 8.0 g for each cycle; GO patients with evidence of recent viral hepatitis, significant hepatic dysfunction, severe cardiovascular morbidity, uncontrolled hypertension, should not be administered i.v. glucocorticoids; diabetes should be well controlled before starting treatment. We strongly recommend that such treatment should only be applied in experienced centers that manage potentially serious adverse events	1, 0000

(Continued)

**Table 1** Continued.

Number	Recommendations	Strength of recommendation and level of evidence
11	Cumulative and single dose of i.v. glucocorticoids An intermediate dose of i.v. glucocorticoids, that is, a starting dose of 0.5 g i.v. methylprednisolone once weekly for 6 weeks, followed by 0.25 g once weekly for 6 weeks, cumulative dose 4.5 g, should be used in most cases of moderate-to-severe and active GO.	1, 0000
12	Cumulative and single dose of i.v. glucocorticoids High-dose regimen, that is, a starting dose of 0.75 g i.v. methylprednisolone once weekly for 6 weeks, followed by 0.5 g once weekly for 6 weeks, cumulative dose 7.5 g, should be reserved for the more severe cases (constant/inconstant diplopia, severe proptosis, severe soft-tissue pathology or involvement) within the moderate-to-severe and active GO spectrum	1, 0000
13	Glucocorticoid withdrawal Clinicians should monitor each individual patient receiving glucocorticoid therapy for response to treatment and adverse events. When drug-induced side effects outweigh benefits, clinicians should consider withdrawing glucocorticoid treatment in favor of another modality, or watchful monitoring	2,0000
14	Local injections of triamcinolone Local subconjunctival/periorcular injections of triamcinolone acetate may be considered when systemic glucocorticoids are absolutely contraindicated	2, 0000
15	Mycophenolate Mycophenolate has a positive efficacy/safety profile in patients with moderate-to-severe and active GO, both as monotherapy and in combination with i.v. glucocorticoids	1, 0000
16	Orbital radiotherapy Orbital radiotherapy is considered an effective second-line treatment for moderate-to-severe and active GO, in combination with glucocorticoids, particularly in the presence of diplopia and/or restriction of extraocular motility	1, 0000
17	Cyclosporine The combination of cyclosporine and oral glucocorticoids is a valid second-line treatment for moderate-to-severe and active GO	1, 0000
18	Azathioprine Consideration can be given to azathioprine as a second-line and glucocorticoid-sparing agent in combination with oral glucocorticoids	1, 0000
19	Teprotumumab Very promising drug with a strong reduction of exophthalmos, diplopia, and improvement of QoL. Currently, second-line option as longer-term data, availability, affordability, costs, and need for subsequent rehabilitative surgery are pending	1, 0000
20	Rituximab Rituximab can be considered a second-line treatment for patients with moderate-to-severe and active GO of recent onset (<12 months) if refractory to i.v. glucocorticoids, as long as dysthyroid optic neuropathy (DON) is excluded. We strongly recommend that such treatment be applied in experienced centers only that manage potentially serious adverse events	1, 0000
21	Tocilizumab Tocilizumab may be given consideration as a second-line treatment for moderate-to-severe and active glucocorticoid-resistant GO	1, 0000
22	First-line treatment for moderate-to-severe and active GO Intravenous methylprednisolone in combination with oral mycophenolate sodium (or mofetil) represents the first-line treatment for moderate-to-severe and active GO	1, 0000
23	First-line treatment for moderate-to-severe and active GO In the more severe forms of moderate-to-severe and active GO, including constant/inconstant diplopia, severe inflammatory signs and exophthalmos > 25 mm, i.v. methyl-prednisolone at the highest cumulative dose (7.5 g per cycle) as monotherapy represents an additional valid first-line treatment	1, 0000

(Continued)

**Table 1** Continued.

Number	Recommendations	Strength of recommendation and level of evidence
24	Second-line treatments for moderate-to-severe and active GO If response to primary treatment is poor and GO is still moderate-to-severe and active, subsequent to careful ophthalmic and biochemical (liver enzymes) evaluation, the following second-line treatments should be considered: <ul style="list-style-type: none"> <li>• Second course of i.v. methylprednisolone monotherapy, starting with high single doses (0.75 g) and a maximal cumulative dose of 8 g per cycle</li> <li>• Oral prednisone/prednisolone combined with either cyclosporine or azathioprine</li> <li>• Orbital radiotherapy combined with oral or i.v. glucocorticoids</li> <li>• Teprotumumab</li> <li>• Rituximab</li> <li>• Tocilizumab</li> </ul>	1, 0000
25	Combination of orbital radiotherapy and i.v. glucocorticoids Based on expert opinion only (as randomized trials are not available), the task force suggests combination of orbital radiotherapy and i.v. methylprednisolone as a potential second-line treatment for moderate-to-severe and active GO	2, 0000
26	Treatment of sight-threatening GO Optic neuropathy should be treated immediately with high single doses of i.v. methylprednisolone (0.5–1 g of methylprednisolone daily for either three consecutive days or more preferably on every second day), and urgent orbital decompression should be performed if response is absent or poor within 1–2 weeks. Recent eyeball subluxation should undergo orbital decompression as soon as possible	1, 0000
27	Treatment of sight-threatening GO Severe corneal exposure should be urgently treated medically or by means of progressively more invasive surgeries in order to avoid progression to corneal breakdown; the latter should be immediately surgically addressed	2, 0000
28	Thyroid treatment in patients with GO Mild and inactive GO: any treatment for hyperthyroidism can be used based on standardized criteria and patient choice	1, 0000
29	Thyroid treatment in patients with GO Mild and active GO: antithyroid drugs (ATDs) or thyroidectomy is preferred and prednisone/prednisolone prophylaxis should be used if RAI treatment is selected	1, 0000
30	Thyroid treatment in patients with GO Moderate-to-severe, longstanding and inactive GO: as for mild and inactive GO, but consideration should be given to prednisone/prednisolone prophylaxis if RAI treatment is selected and risk factors (smoking, high TSHR-Ab) are present	1, 0000
31	Thyroid treatment in patients with GO Moderate-to-severe and active GO: hyperthyroidism should be treated with ATDs until treatment of GO is completed	1, 0000
32	Thyroid treatment in patients with GO Sight-threatening GO: in this emergency condition, treatment of GO is an absolute priority; hyperthyroidism should be treated with ATDs until treatment of GO is completed	1, 0000

asymmetric exophthalmos, suspected optic neuropathy, and euthyroidism with normal thyroid serology, while orbital CT is indicated prior to decompression surgery (19, 20, 21).

### Early referral to specialized centers

In the last 30 years, a reduction in the incidence of GO in GD patients, as well as of its severity when present, has been reported (2, 3, 26) and recently confirmed by meta-analyses and meta-regression of published studies (27).

This secular trend is multifactorial in origin (e.g. decrease in smoking habits, earlier diagnosis, and better control of thyroid dysfunction). Improved interaction between endocrinologists and ophthalmologists leads to early diagnosis and treatment. In addition, mild GO can progress to a more severe disease requiring expert advice and guidance for a general management plan (28). Therefore, it is fundamental to refer patients with overt GO and those at risk for deterioration of GO (mild and active GO, smokers, severe/unstable hyperthyroidism, high serum level of thyrotropin receptor antibodies (TSHR-Ab)) (8, 29) to thyroid-eye clinics, namely

**Table 2** Assessment of activity by the clinical activity score (CAS)\*. CAS < 3 = inactive GO; CAS ≥ 3 = active GO. A ten-item CAS, including an increase in exophthalmos of ≥2 mm, a decrease in eye motility of ≥8° or a decrease in visual acuity in the last 1–3 months, is useful to assess progression of GO after the first visit.

#### Assessment of activity

1. Spontaneous retrobulbar pain
2. Pain on attempted upward or downward gaze
3. Redness of eyelids
4. Redness of conjunctiva
5. Swelling of caruncle or plica
6. Swelling of eyelids
7. Swelling of conjunctiva (chemosis)

\*Modified according to Wiersinga *et al.* (14) and reproduced with permission.

specialized centers providing combined endocrine and ophthalmic expertise (30, 31), as this will provide an accurate and timely diagnosis to improve prognosis and QoL. Indeed, GO patient satisfaction was greater in those who attended such clinics (32). Primary care physicians, general practitioners, internists, endocrinologists, or general ophthalmologists can manage the mildest cases without risk factors unless progression occurs (Recommendation #2).

### Assessment of treatment outcomes

Evaluation of treatment outcome should be standardized by using both a subjective primary outcome (patient-reported outcome, PRO) and an objective primary outcome (clinician-reported outcome, CRO), assessed at a fixed time interval after the end of the intervention.

**Table 3** Classification of severity of Graves' orbitopathy (GO).

Classification	Features
Mild GO	<p>Patients whose features of GO have only a minor impact on daily life that have insufficient impact to justify immunomodulation or surgical treatment. They usually have one or more of the following:</p> <ul style="list-style-type: none"> <li>• minor lid retraction (&lt;2 mm)</li> <li>• mild soft-tissue involvement</li> <li>• exophthalmos</li> <li>• &lt;3 mm above normal for race and gender</li> <li>• no or intermittent diplopia and corneal exposure responsive to lubricants</li> </ul>
Moderate-to-severe GO	<p>Patients without sight-threatening GO whose eye disease has sufficient impact on daily life to justify the risks of immunosuppression (if active) or surgical intervention (if inactive). They usually have two or more of the following:</p> <ul style="list-style-type: none"> <li>• lid retraction ≥ 2 mm</li> <li>• moderate or severe soft-tissue involvement</li> <li>• exophthalmos ≥ 3 mm above normal for race and gender</li> <li>• inconstant or constant diplopia</li> </ul>
Sight-threatening (very severe) GO	<p>Patients with dysthyroid optic neuropathy and/or corneal breakdown</p>

The preferred PRO is the validated disease-specific GO-QoL questionnaire (33, 34). The most appropriate CRO depends on the type of intervention. For moderate-to-severe and active GO, a recently revised composite index is suggested (30). It is composed of entirely objective measures: ≥2-mm reduction of lid aperture, ≥1 point reduction in five-item CAS (excluding subjective, patient-reported spontaneous or gaze-evoked pain), ≥2 mm reduction in exophthalmos, ≥8° increase of eye muscle duction (34). Improvement in ≥2 features in one eye without deterioration in the other eye might be considered a positive response to treatment (34). Other individual ocular, serological, and imaging features can be included as secondary outcomes, including exophthalmos, eyelid aperture, ocular motility, visual acuity, CAS, intraocular pressure, orbital volume assessment, MRI, and TSHR-Ab measurement. Optimally, the outcome of treatment should be assessed 3 months after the last therapeutic intervention (34), but, in addition, changes after 6 months can also be considered.

### General measures for all patients (Recommendations #3–6)

#### Control of risk factors

Every effort should be made to remove risk factors in order to prevent de novo occurrence and/or progression of GO, regardless of clinical phenotype, when a patient is suspected with GD. Adequate control of thyroid dysfunction is of paramount importance. Both hyper- and hypothyroidism negatively impact GO (35, 36, 37). In line with the expression of the TSHR as autoantigen on orbital target cells (38, 39) in patients with GD/GO, high

serum concentrations of *TSHR-Ab* (>five-fold increase) are associated with the presence of GO both in children and adults with GD and Hashimoto's thyroiditis (40, 41, 42, 43). Although neither regularly done in commercial laboratories nor routinely available to the clinician, dilution analysis of serum TSHR-Ab is both predictive for the occurrence of GO (positive and negative predictive values of 100% with a cut-off dilution titer > 4) (29), as well as for the response to antithyroid treatment of associated Graves' hyperthyroidism (42, 44).

All patients with GD, irrespective of the presence of GO, should be urged to quit smoking. The association between GO and smoking is evidence-based (3, 45, 46). Smoking increases the risk of GO in patients with GD (3); smokers have more severe GO (3); development or progression of GO after radioactive iodine (RAI) treatment is more frequent in smokers (47, 48); smokers have a delayed or worse outcome of immunosuppressive treatments (47, 49, 50); smoking cessation is possibly associated with a better outcome of GO (51).

RAI bears a consistent risk of causing progression and/or *de novo* occurrence of GO (48, 52, 53, 54, 55). In a large RCT, progression of GO occurred in 23 of 150 patients given RAI (15%), being persistent in 8 (5%), hence requiring immunosuppressive treatment for GO (54). Both *de novo* occurrence and progression of GO are more likely in smokers (47, 48), in patients with duration of GD <5 years (56), and less likely in patients with long-standing and inactive GO (37). RAI-associated progression of GO can be prevented by a concomitant short-term course of oral prednisone (52, 54, 56, 57). The original regimen used a starting daily dose of 0.3–0.5 mg/kg/bodyweight, gradually tapered and withdrawn after 3 months (47). Lower doses of oral prednisone (0.1–0.2 mg/kg/bodyweight as starting dose, gradually tapered and withdrawn after 6 weeks) (58) showed similar beneficial effects. As previously recommended (7), the 0.3–0.5 mg dose should be used in patients who are at risk for progression and/or *de novo* development of GO (smokers, high TSHR-Ab levels, severe hyperthyroidism, preexisting GO). Prophylaxis using low-dose i.v. glucocorticoids has been proposed, but this requires 1 day of hospitalization per week for 4 weeks (56). Glucocorticoid prophylaxis is not only effective but also safe (59).

High cholesterol is an emerging and potential risk factor for GO (60). The use of statins was associated with a reduced risk of GO occurrence in a large cohort retrospective study (61) and in a retrospective registry-based study (62). Association of high total and LDL-cholesterol with the presence of GO was reported in one cross-sectional and

one retrospective study (63, 64). Finally, in a retrospective study, the outcome of GO following i.v. glucocorticoid treatment was worse in patients with high LDL cholesterol (65). These findings may reflect a pro-inflammatory action of cholesterol. Alternatively, they might be related to an anti-inflammatory effect of statins, irrespective of cholesterol levels. RCTs are lacking, but control of hypercholesterolemia by statins may be considered in patients with GO.

### Local treatments

Ocular surface inflammation and dry eye are frequent in GD patients; regardless of the presence of overt GO (66, 67, 68). In GO patients, several factors contribute to drying of the eye, that is, increased width of the palpebral fissure, exophthalmos, blinking rate, lid lag, lagophthalmos, poor Bell's phenomenon due to restrictive elevation deficit, and altered tear film osmolality (69, 70, 71). Treatment with artificial tears during the day and ophthalmic gels/ointments with a possible taping of the lids or using swimming goggles at nighttime when severe lagophthalmos is present in the absence of an adequate Bell's phenomenon are recommended to GO patients since first observation and to patients with GD without overt GO but with dry eye symptoms (72). Botulinum toxin injection in the levator muscle may reduce the palpebral aperture (73).

### Management of mild GO

Most patients with mild GO experience spontaneous resolution of eye manifestations. Therefore, a watchful strategy and local treatments are sufficient (8) (Fig. 1). Patients living in selenium-deficient areas can benefit from oral selenium supplementation. A randomized, double-blind, placebo-controlled trial of patients with mild GO, performed in Europe, reported a higher rate of improvement in both GO-QoL and overall ophthalmic outcome and a lower rate of progression to more severe GO in patients receiving sodium selenite (200 µg (91.2 µg selenium) daily for 6 months), compared to the placebo group (74). The benefit of selenium was maintained 6 months after treatment withdrawal. According to country availability, sodium selenite can be replaced by seleniomethionine (100 µg daily). Whether selenium administration is of benefit in selenium-replete areas has to be confirmed. An European survey has shown that selenium supplementation is recommended by the majority of clinicians, both in patients

## MILD GO

## General recommendations

- Refrain from smoking
- Treat thyroid dysfunction (preferably with antithyroid drugs, especially if risk factors for deterioration/progression of GO are present (see below))
- Avoid iatrogenic hypothyroidism in treating patients with GD/GO
- Referral to thyroid-eye clinics if risk factors present (active GO, smoker, high TSHR-Ab, unstable / severe hyperthyroidism)
- Search for dry eye syndrome

## Management

## Local treatment

- Artificial tears, especially when dry eye present
- Ophthalmic gels (cornea protection during the night)

## Systemic adjunct therapy for active GO

- Selenium supplementation for six months (fasting intake)

Quality of life markedly impaired



Discuss low dose immunomodulatory (active GO) or rehabilitative surgery (inactive GO) following extensive counseling and shared decision

Figure 1

Algorithm for the management of mild Graves' orbitopathy. TSHR-Ab, thyrotropin receptor antibody; GO, Graves' orbitopathy; GD, Graves' disease.

with mild and moderate-to-severe GO (75), but there is no evidence of a beneficial adjuvant effect of selenium in patients with moderate-to-severe and active GO.

While a wait-and-see strategy is feasible in the majority of patients with mild GO, a very few patients may experience or develop a profound impact on QoL: in these exceptional patients, low-dose immunomodulation may be proposed if GO is active or rehabilitative surgery if GO is inactive, subsequent to extensive counseling and shared decision (8) (Recommendations #7–8).

### Management of moderate-to-severe and active GO

After an initial phase in which inflammation and its manifestations are predominant (active phase), GO stabilizes (plateau phase) and then slowly remits leaving

typical residual signs and symptoms (inactive phase); the whole process (natural history) is believed to last 18–24 months in untreated patients (3). In patients with moderate-to-severe and active GO, the initial goal is to shorten the active phase of the disease and improve subjective and objective eye manifestations. Results of treatment are usually better if GO is treated early, within 1 year from its onset. Efficacy of immunosuppressive therapy varies between 50 and 80% according to the published trials (76) but rarely leads to a complete satisfactory response. Residual inactive disease benefits from rehabilitative surgery. Non-responders may require a second course of immunosuppressive therapy using different drugs/treatments, alone or in combination. Few patients still remain unresponsive or partially responsive and will need a surgical approach.

Extensive counseling is required when discussing the treatment plan. The patient should be informed that



he/she would be engaged in a complex journey, clearly explaining the benefits and risks of the various therapeutic options. Response to initial therapy cannot be predicted. The patient should be aware that additional medical and/or surgical treatments might be needed, particularly rehabilitative surgery, even in responders, in an attempt to restore the pre-disease eye appearance and function. Selection of treatment follows several considerations, for example, evidence-based effectiveness, short-term/long-term safety, evaluation of costs, reimbursement by the health system, drug-availability, infrastructure facilities for delivering highly specialized treatments, and personal choice of the informed patient within a shared decision-making process (Recommendation #9).

### Systemic and locally injected glucocorticoids (Recommendations #10–14)

High-dose systemic glucocorticoids have potent anti-inflammatory and immunosuppressive effects (77, 78) that have been applied successfully for the management of moderate-to-severe and active GO. Intravenous glucocorticoids have been indicated as the first-line treatment in moderate-to-severe and active GO (22, 79). A proof-of-concept RCT showed a significant improvement of GO outcome in patients treated with i.v. methylprednisolone compared to placebo (response rate 83% vs 11%) (80). Although oral glucocorticoids are effective, glucocorticoids are preferentially administered i.v. as the i.v. route has been shown in RCTs to be more effective (77–88% vs 51–63%) and better tolerated (81, 82). The most common protocol employs a cumulative dose of 4.5 g methylprednisolone, given in 12 weekly infusions (six infusions of 0.5 g, followed by six infusions of 0.25 g) (82). This 4.5 g regimen is very well tolerated (83) and significantly improves QoL (84). While this regimen is appropriate for most patients, a higher cumulative dose of 7.5 g (starting with 0.75 g as a single i.v. dose) is reserved for more severe cases within the spectrum of moderate-to-severe and active GO, as the higher dose bears a higher risk of drug-induced adverse events (AEs) (85). Safety data suggest that, with the exception of sight-threatening GO, single i.v. doses should not exceed 0.75 g, cumulative doses should be less than 8.0 g per cycle, and consecutive-day therapy should be avoided, because these schedules are associated with a significantly higher rate and clinically relevant glucocorticoid-induced AEs, including liver toxicity and serious cardiovascular AEs (86, 87, 88, 89, 90).

Infusions should be performed slowly (1–2 h) under strict surveillance. Therefore, prior to starting treatment

and after ruling out infections (white blood cell count), cardiovascular risk, liver enzymes, and markers of viral hepatitis are evaluated, in order to assess risks and contraindications (8). In addition, liver enzymes are closely monitored during treatment (89). Recent viral hepatitis, significant hepatic dysfunction, severe cardiovascular morbidity, or psychiatric disorders represent absolute contraindications to i.v. glucocorticoid treatment (78, 79), while diabetes and hypertension should be well controlled before starting treatment (8). Bone protection is recommended, and proton pump inhibitors are used as appropriate (8). Response to i.v. glucocorticoids usually occurs early, but it may be delayed to the second half of the treatment course (91). This is why partial responders to i.v. glucocorticoids should be offered to complete the 12-week regimen. In contrast, a clinical deterioration of clinical ophthalmic signs and symptoms requests a shift to second-line treatments (8, 91).

Intravenous glucocorticoid treatment needs to be carried out in specialized centers and facilities that may not be easily available in all countries. This partly explains why the oral route is still widely used either alone (92) or after initiating a treatment course with a few i.v. infusions (93) to reduce hospital admissions. In the case of oral glucocorticoids, treatment should start, as suggested by several RCTs (77, 81, 82), either with a fixed dose of 100 mg prednisone/prednisolone or, preferably, 1 mg/kg bodyweight and be gradually tapered down by 5–10 mg/week until withdrawal (4–6 months). Combination with other treatments, including orbital radiotherapy or non-steroidal immunosuppressive drugs, (i.e. mycophenolate or cyclosporine) may work as a steroid-sparing procedure and increase the effectiveness of oral glucocorticoids.

Local (subconjunctival or parabulbar) glucocorticoid administration has been used in a few patients. In a RCT, retrobulbar injections of methylprednisolone acetate were less effective than systemic glucocorticoids when combined with orbital cobalt radiotherapy (94). In a prospective, single-blind, placebo-controlled RCT, orbital injections of triamcinolone acetate into the inferolateral quadrant (4 weekly injections of 40 mg) reduced diplopia and extraocular muscle size (95). Furthermore, in a small RCT, subconjunctival upper eyelid injections of triamcinolone (1–3 injections of 20 mg) were reported to be effective for the treatment of upper eyelid retraction in patients with a short duration of GO (96). However, local glucocorticoid treatment has a significant risk of intraocular pressure elevation, may be associated with increased orbital lipomatosis, and bears a small but significant risk of retrobulbar hemorrhage, especially in patients with dual

platelet inhibition (97, 98). Hence, local glucocorticoids may be considered in patients with contraindications to systemic administration of glucocorticoids only.

### Mycophenolate (Recommendation #15)

Mycophenolate competitively and reversibly inhibits inosine monophosphate dehydrogenase, resulting in decreased antibody production by B cells and dual antiproliferative effect on both B- and T-cells (99). Mycophenolate induces apoptosis of activated T-cells, inhibits expression of adhesion molecules and recruitment of immune cells (100). In addition, mycophenolate inhibits fibroblast proliferation and functions (101, 102, 103, 104). The drug is available worldwide as mycophenolate mofetil and/or enteric-coated mycophenolate sodium (105). Fractionated doses per day taken with the meals improve gastrointestinal tolerance. A systematic review of the gastrointestinal side effects between the two formulations did not demonstrate significant differences between gastro-intestinal-related QoL for patients using either form as maintenance immunosuppression (106).

In a single-center trial, 174 euthyroid patients with moderate-to-severe and active GO were randomized to either an unusual combination of three infusions of i.v. glucocorticoids followed by oral glucocorticoids or mycophenolate mofetil (1 g daily), both for 24 weeks (107). Mycophenolate mofetil demonstrated a superior overall response rate (79%/91% at week 12/24 vs 51%/68% in the glucocorticoid group). Disease inactivation was observed in 94% of mycophenolate mofetil group (vs 69% in the combined glucocorticoid group) at week 24. Mycophenolate mofetil also performed well in proptosis and diplopia. Six percent of glucocorticoid patients developed disease reactivation, while none in the mycophenolate mofetil group relapsed.

In the EUGOGO's observer-masked multicenter trial (108, 109), 164 euthyroid patients with moderate-to-severe and active GO were randomized to weekly i.v. methylprednisolone for 12 weeks or a combination of i.v. methylprednisolone for 12 weeks and mycophenolate sodium 0.72 g daily (which is equivalent to 1 g mycophenolate mofetil/day) for 24 weeks. In the intention-to-treat population at 12 weeks, responses were observed in 36 (49%) of 73 patients in the monotherapy group and 48 (63%) of 76 patients in the combination group, giving an odds ratio (OR) of 1.76 (95% CI: 0.92–3.39,  $P=0.089$ ). At week 24, 38 of 72 patients remaining in the monotherapy group and 53 of 75 patients remaining in the combination therapy group had responded to treatment (OR: 2.16,

CI: 1.09–4.25,  $P=0.026$ ). At week 36, 31 of 68 patients in the monotherapy group and 49 of 73 patients in the combination group had a sustained response (OR: 2.44, CI: 1.23–4.82,  $P=0.011$ ). Thus, the combination group displayed statistically significant superior response rate at week 24 (71% vs 53%) and a sustained response rate at week 36 (67% vs 45.5%). Overall, combination treatment demonstrated more significant improvements in CAS, swelling of eyelids and caruncle, orbital pain, chemosis, downgaze duction and elevation, as well as GO-QoL visual functioning score.

Evaluating both randomized trials, mycophenolate-treated groups demonstrated superior response rates at 12 (107), 24 (107, 108), and 36 weeks (108) when compared to their respective glucocorticoid monotherapy groups. Approximately 70% (vs 90% in the mycophenolate group) and 30% (vs 60–70% in the mycophenolate group) of patients achieved endpoints in most individual visual parameters of activity and severity, respectively. In addition, the mycophenolate sodium+glucocorticoid group of the EUGOGO trial performed better than mycophenolate alone (107) in terms of improvement of pain and eye movement. However, longer-term follow-up and subsequent rehabilitative surgery data are currently not available and may be regarded as limitations of both RCTs.

Higher mean age, more prevalent smoking habit, longer disease duration, and a greater proportion of TSHR-Ab-positive patients may explain the lower response rates in the EUGOGO trial. Neither trial reported any serious infection nor treatment-related mortality (110, 111). The combination treatment did not increase the risk of infection and hepatotoxicity when compared to i.v. methylprednisolone monotherapy. Furthermore, 'real-world' efficacy and safety of mycophenolate mofetil in patients with active moderate-to-sight-threatening GO was demonstrated over a 4-year observation period (112). Therefore, the risk-benefit ratio of low-dose mycophenolate, either as monotherapy or in combination with i.v. glucocorticoids treatment in active moderate-to-severe GO, is highly favorable given its reassuring safety profile and promising efficacy (110, 111). Hence, the combination of low-dose mycophenolate sodium and i.v. methylprednisolone was both safe and affordable in view of its superior efficacy compared to the current standard of care.

### Orbital radiotherapy (Recommendation #16)

Orbital radiotherapy for GO has been shown by several RCTs which were found to be more effective than sham

irradiation in improving diplopia and ductions (113, 114), although its efficacy was questioned by two additional RCTs (115, 116). In another RCT, orbital radiotherapy was found to be as effective as oral prednisone (117), and other RCTs have shown that orbital radiotherapy synergistically potentiates the effects of oral glucocorticoids (118, 119). RCTs showing that this synergistic effect holds true using i.v. glucocorticoids are missing. However, two retrospective studies showed that a combination of orbital radiotherapy and i.v. glucocorticoids was more effective than i.v. glucocorticoids alone in improving eye motility and reducing GO severity (120, 121). Usually, a 20 Gray (Gy) cumulative dose per orbit fractionated in ten daily doses over 2-weeks is given (122). However, a regimen of one Gy per week over 20-weeks was shown to be equally effective and better tolerated (123). Mild and transient exacerbation of ocular symptoms may occur during orbital radiotherapy, which is controlled by concomitant administration of low-dose oral prednisone. Although orbital radiotherapy is safe (124, 125, 126, 127), it should be avoided in patients with hypertensive or diabetic retinopathy, or, in view of a remote carcinogenic risk, in patients younger than 35 years (8). In a 17-year long-term follow-up study comparing a single dose of one Gy vs two Gy, radiation-induced retinopathy was observed in 5% of patients with GO, diabetes mellitus, and hypertension approximately 10 years after orbital radiotherapy, however, in none of those irradiated with the lower dose (128). In summary, orbital radiotherapy is effective, particularly on ocular motility, and safe, being devoid of major adverse events even after a long-term follow-up (122).

### Cyclosporine (Recommendation #17)

Cyclosporine is a potent immunosuppressive agent that inhibits the calcineurin pathway reducing T-cell proliferation and IL-2 secretion. Two small, early RCTs have assessed its efficacy in patients with moderate-to-severe GO. The combination of cyclosporine (initial dose: 5–7.5 mg/kg bodyweight/day) and oral prednisolone (initial dose: 50–100 mg/day) had a better ophthalmic outcome and a lower relapse rate than oral prednisolone monotherapy (129). In another study (130), significantly fewer patients responded to cyclosporine (7.5 mg/kg bodyweight/day) as compared to oral prednisolone (initial dose 60 mg/daily) (22% vs 61%). However, more than half of the non-responders to either drug alone showed subsequent improvement with prednisolone–cyclosporine combination confirming the potential

beneficial effect of combined cyclosporine–glucocorticoid treatment and its superiority vs either cyclosporine or oral glucocorticoid monotherapy. Of note, there are no RCTs comparing cyclosporine with i.v. glucocorticoids for the treatment of GO.

### Azathioprine (Recommendation #18)

Azathioprine is an antiproliferative agent with a similar mode of action to mycophenolate, frequently used as a 'steroid-sparing agent' in autoimmune/inflammatory conditions. Azathioprine was ineffective in GO as a single agent (131), but observational studies suggested benefits in combination with low-dose glucocorticoids (132). In the randomized and blinded CIRTED study ( $n = 126$ ), azathioprine over 12 months was studied in combination with high-dose oral glucocorticoids and orbital radiotherapy in a factorial designed trial (116). Although the majority of patients returned for primary end-point review (82%), 66% of participants allocated to azathioprine and 45% of those allocated to placebo did not complete the full 48 weeks of treatment. Withdrawals from the azathioprine group were for known AEs of azathioprine. Despite low adherence rates, in intention-to-treat analyses, the point estimate for the OR for improvement in patients treated with azathioprine was substantial (OR: 2.56, 95% CI: 0.98–6.66;  $P = 0.054$ ) and a sensitivity analysis in which patients who withdrew during the trial were recorded to unfavorable outcomes regardless of their status at 48 weeks, the effect of azathioprine treatment was enhanced (OR: 3.65, 95% CI: 1.34–9.86;  $P = 0.011$ ). In addition, in a *post-hoc* per protocol analysis of patients who completed their allocated therapy, the OR for improvement on azathioprine was large (OR: 6.83, 95% CI: 1.66–28.1;  $P = 0.008$ ). The major benefit was a reduction in the relapse rate after glucocorticoid withdrawal. Hence, azathioprine may be a valuable steroid-sparing agent when continued after an oral glucocorticoid taper, although it is frequently not well tolerated. Benefits in combination with i.v. glucocorticoids are unknown.

### Teprotumumab (Recommendation #19)

The insulin-like growth factor-1 (IGF-1) receptor is over-expressed in GO orbital fibroblasts and lymphocytes (133, 134). It forms a functional complex with the TSHR and mediates TSHR downstream signaling (135). Teprotumumab is a fully humanized immunoglobulin (Ig) G1 monoclonal inhibiting antibody, which binds to the extracellular portion of IGF-1R and blocks its

activation and signaling by endogenous ligands. Binding of teprotumumab also leads to internalization and degradation of IGF-1R resulting in up to 95% reduction of accessible receptor protein on the cell surface (135).

The safety and efficacy of teprotumumab were evaluated sequentially in two RCTs, which comprised 170 patients with moderate-to-severe and active GO (136, 137). Both trials had similar designs and patients were randomly assigned to teprotumumab (83 patients; once every 3 weeks i.v. for eight doses over 24 weeks) or placebo (87 patients). Seventy-three percent in teprotumumab groups (vs 14% in placebo groups) were overall responders with both CAS and proptosis improvement. Individually, CAS of 0–1 (62% vs 22%) and proptosis response (77% vs 15%) were much more common in teprotumumab groups. Proptosis response occurred early at week 6 in most patients. The mean reduction in proptosis by week 24 ranged from 2.9 to 3.3 mm. Teprotumumab treatment was also associated with a significant improvement in GO-QoL score. Recently, systematic analyses and off-treatment follow-up results from the two RCTs were published (138). One year after the final dose, integrated proptosis, diplopia, and composite responses were 67, 69, and 83%, respectively. In the teprotumumab group, orbital decompression surgery was required in a few patients during the follow-up observation period and dysthyroid optic neuropathy (DON) occurred in one patient 4 months after the last teprotumumab infusion. The most common AEs reported with teprotumumab included muscle spasms (25%), nausea (17%), alopecia (13%), diarrhea (13%), fatigue (10%), hearing impairment (10%), and hyperglycemia (8%). Also, teprotumumab is contraindicated for those with inflammatory bowel disease and in pregnancy. In the systematic analysis, most teprotumumab AEs were mild-moderate during treatment, with three related serious AEs (diarrhea, infusion reaction, and Hashimoto's encephalopathy/confusion) leading to study discontinuation. In line with this, a case of serious teprotumumab-induced amyloid encephalopathy was recently reported, which was unresponsive to high-dose glucocorticoids or immunoglobulin G therapy, but remitted after plasmapheresis (139). The current dosing regimen of teprotumumab has proven effective for GO; however, dose-ranging studies including variable concentrations, infusion frequencies, and durations of teprotumumab therapy in the setting of GO have not been performed (140). Therefore, although teprotumumab has become the first drug approved by the US Food and

Drug Administration for the treatment of adult GO, its incorporation into routine clinical practice is currently limited by the lack of comprehensive long-term efficacy and safety data, absence of head-to-head comparison with i.v. glucocorticoids, restricted geographical availability, reimbursement (outside the US), and costs.

### Rituximab (Recommendation #20)

Rituximab is a chimeric human and mouse MAB against CD20 surface antigen expressed on B cells that causes immunosuppression through B-cell depletion. After several retrospective case series (141, 142, 143) suggested a potential benefit of rituximab for the treatment of GO, two double-blind, but low-powered single-center RCTs have evaluated rituximab in patients with moderate-to-severe and active GO with conflicting results. The US study (144) randomized 25 patients to receive two infusions of either rituximab (1000 mg each) or placebo (saline) 2 weeks apart: no additional advantage of rituximab over placebo was found in reducing CAS or severity of GO at 24 or 52 weeks. In contrast, the Italian study (145) demonstrated better ophthalmic and QoL outcomes with rituximab as compared to i.v. glucocorticoids: 32 patients were randomly assigned to receive either rituximab (two doses of 1000 mg 2 weeks apart or a single dose of 500 mg) or i.v. glucocorticoids (cumulative dose, 7.5 g). At 24 weeks, all patients treated with rituximab showed inactivation of GO as compared to 69% in the i.v. glucocorticoid group. At 52 weeks, none in the rituximab group and 31% in the i.v. glucocorticoid group had reactivation of GO (145). As compared to the US study (144), participants in the Italian trial had a shorter average duration of GO (4.5 vs 12.2 months), which may explain the discrepant results.

In the above studies, DON developed in two patients and vasculitis in one rituximab-treated patient (144). A severe cytokine release syndrome presenting with marked periorbital edema and decrease of vision, then controlled with glucocorticoids, occurred in two patients (145). A recent non-randomized prospective study of 17 patients (8 steroid naive, 9 unresponsive to i.v. glucocorticoids) has suggested an efficacy of a low dose (100-mg single infusion) of rituximab in moderate-to-severe and active GO (146). Over 90% of these patients showed disease inactivation by 12 weeks, and no patient had reactivation after a 76-week follow-up. Mild infusion-related AEs frequently seen with the higher dose of rituximab were rare; nevertheless, one patient developed a cytokine release syndrome (146).

### Tocilizumab (Recommendation #21)

Tocilizumab is a humanized MAB against the interleukin (IL)-6 receptor approved for use in rheumatoid arthritis. In addition to playing a role in T and B cell activation as a pro-inflammatory cytokine, IL-6 also acts directly on orbital pre-adipocytes to promote volume expansion (147). In an RCT of GO patients considered to have failed initial glucocorticoid therapy ( $n=32$ ), subjects treated with i.v. tocilizumab monotherapy on weeks 0, 4, 8, 12 showed greater reductions in CAS (86% achieving CAS <3 vs 35% in the placebo group,  $P < 0.005$ ) at week 16 (148). Tocilizumab was generally well-tolerated, but there was a higher rate of infections and headache in the tocilizumab group; the benefit was predominantly on soft-tissue signs (148). In an uncontrolled observational study of 48 patients, resistant to established therapies (mostly i.v. glucocorticoids, 90%), tocilizumab given monthly i.v. or weekly subcutaneously was well tolerated and the majority of patients showed improvement (92%) (149). Likewise, a small study of eight glucocorticoid-resistant patients with moderate-to-severe and active GO showed a beneficial effect of tocilizumab on CAS and exophthalmos (150). Similar findings were recently reported in a single-center retrospective observation over 9 years with 54 patients analyzed (151), nevertheless larger RCTs including tocilizumab in naive patients with GO of short duration are warranted. Currently, data suggest that tocilizumab may cause rapid resolution of inflammatory signs in glucocorticoid-resistant moderate-to-severe and active GO.

### Other immunomodulators

Intravenous immunoglobulin treatment resulted in decreased specific autoantibody titers and clinical improvement in several autoimmune diseases (152). The random i.v. administration of anti-idiotypic immunoglobulins (1 g/kg/bodyweight) in patients with moderate-to-severe and active GO was as effective as (62% response rate) and better tolerated than oral prednisolone (153). High costs, the need for i.v. administration, and its small potential risk for transmitting infectious agents limit the routine use of i.v. immunoglobulins in the treatment of GO. In comparison, when randomly tested in moderate-to-severe and active GO, ciamexone did not show any beneficial effect vs placebo (154). Also negative was four RCTs evaluating somatostatin-analogs (either octreotide or lanreotide) in GO (155, 156, 157, 158). The level of tumor necrosis factor- $\alpha$  (TNF $\alpha$ ) is elevated in

GO patients compared to controls (159, 160). However, selected anti-TNF $\alpha$  agents tested in uncontrolled, small studies of GO patients had limited efficacy (161, 162, 163). Adding methotrexate to i.v. glucocorticoids in an uncontrolled small study in patients with active GO was safe and allowed reduced administration of glucocorticoids without compromising their efficacy (164).

### First-line and second-line treatments for moderate-to-severe and active GO

When reviewing all currently published RCTs and evaluating pros and cons, efficacy and safety, as well as comparing the present evidence-based reports with those available 6 years ago, the following first-line treatments (Fig. 2) and alternative second-line approaches (Fig. 3) are recommended.

#### First-line treatments

As demonstrated by two large RCTs (107, 108) including more than 300 patients with moderate-to-severe and active GO and involving mycophenolate and glucocorticoids, this combination therapy shows a beneficial efficacy/safety profile (110) with a statistically significant and clinically relevant higher benefit than i.v. glucocorticoid monotherapy. Hence, and as shown in Fig. 2, the combination of i.v. methylprednisolone (moderate cumulative dose of 4.5 g over 12 weeks)+mycophenolate sodium 0.72 g per day for 24 weeks is recommended as first-line treatment for most patients with moderate-to-severe and active GO. If the enteric-coated mycophenolate sodium is not available, mycophenolate mofetil is administered (1 g of mofetil is equivalent to 0.72 g of the sodium formulation).

In the most severe forms (including constant/inconstant diplopia, severe soft-tissue signs) within the spectrum of moderate-to-severe and active GO, a higher cumulative dose of i.v. methylprednisolone (7.5 g) as monotherapy is also recommended as an alternative first-line approach. RCTs comparing the higher dose (7.5 g) in combination with mycophenolate to i.v. glucocorticoid monotherapy are not available.

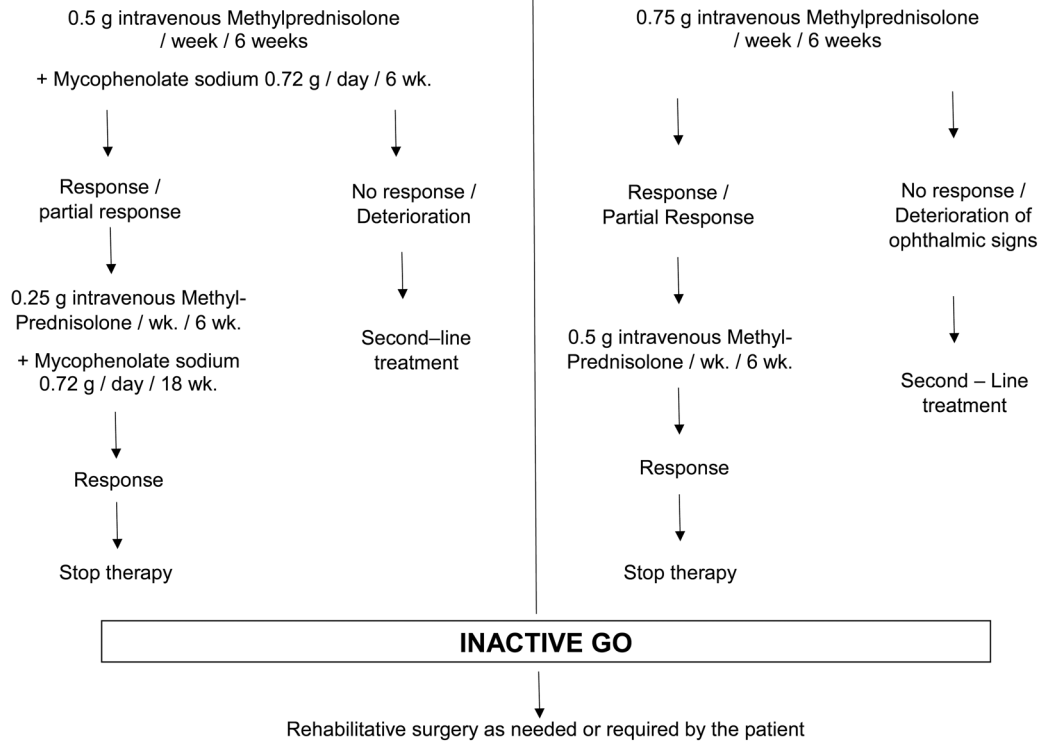
#### Second-line treatments

As already recommended in the 2016 ETA/EUGOGO guidelines (8) and subsequent to a careful ophthalmic and

### MODERATE-TO-SEVERE AND ACTIVE GO FIRST – LINE TREATMENT

#### General Recommendations

- Referral to thyroid-eye clinic for counseling and treatment plan shared with patient
- Stop smoking
- Treat thyroid dysfunction with antithyroid drugs
- Avoid iatrogenic hypothyroidism in treating patients with GD/GO

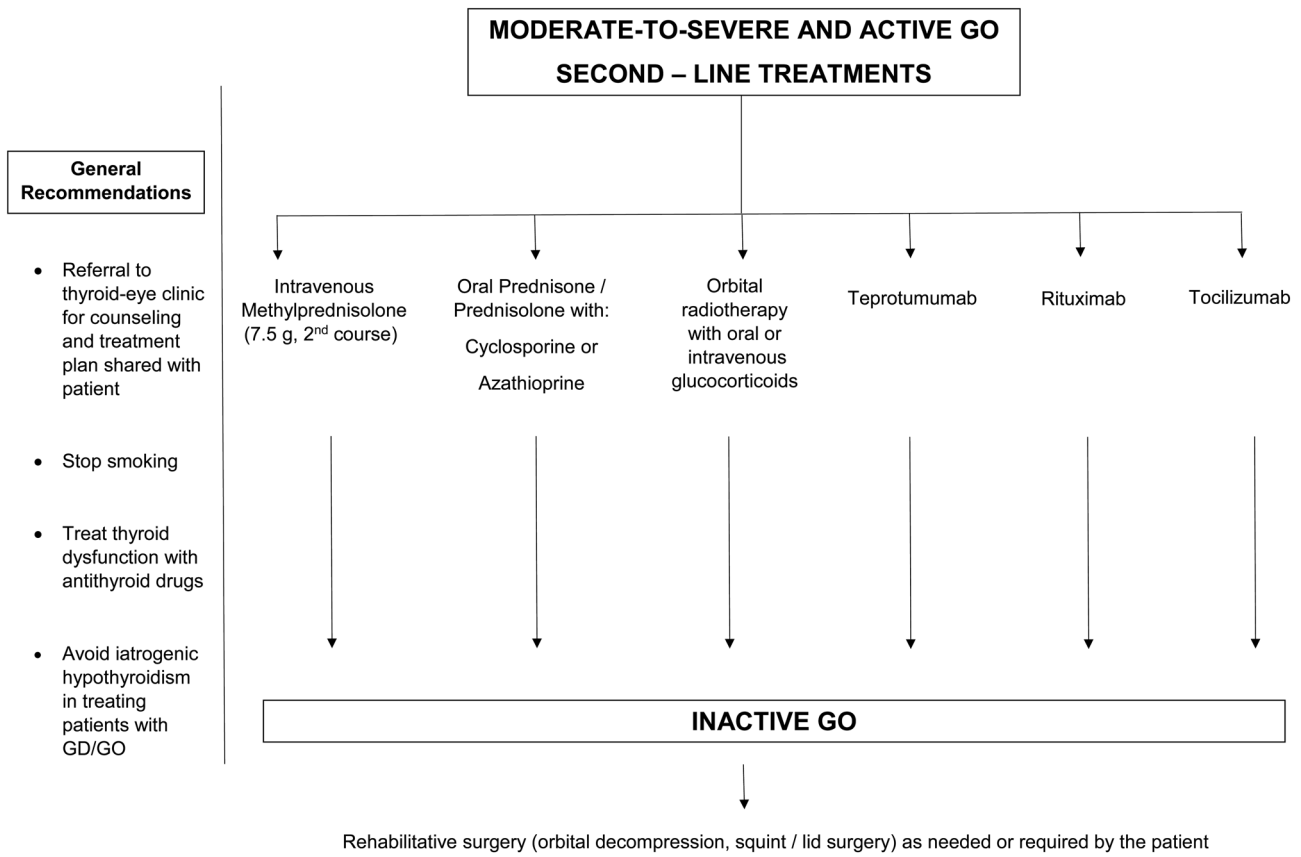


**Figure 2**

Algorithm for the first-line management of moderate-to-severe and active Graves' orbitopathy. The combination of a moderate cumulative dose of i.v. methylprednisolone + a moderate daily dose of oral enteric-coated mycophenolate sodium (first pathway) is the EUGOGO recommended first-line treatment for patients with moderate-to-severe and active GO (with or without diplopia). If mycophenolate sodium is not available, the other formulation mycophenolate mofetil is administered. Of note, 0.72 g of mycophenolate sodium is equivalent to 1 g of mycophenolate mofetil. An alternative first-line treatment is the administration of high single doses of i.v. methylprednisolone starting with 0.75 g per day and week for six consecutive weeks. This regimen is recommended for patients with constant/inconstant diplopia, severe proptosis, and severe inflammatory soft-tissue changes. GO, Graves' orbitopathy; GD, Graves' disease.

biochemical (liver enzymes) evaluation, after 3–4 weeks, a second course of i.v. methylprednisolone monotherapy administering the higher cumulative dose of 7.5 g and starting with single doses of 0.75 g for 6 weeks is a further acknowledged and valid second-line therapy. Of note, a cumulative dose of 8 g i.v. methylprednisolone per cycle is allowed. Alternatively, the combination of oral prednisone/prednisolone and cyclosporine is recommended, as two RCTs demonstrated the benefits of this combination (8, 129, 130). In addition, azathioprine can be used together with oral glucocorticoids because of its steroid-sparing action in one RCT (Fig. 3).

The largest clinical experience as of today for an alternative evidence-based therapy is with the combination of oral prednisone/prednisolone and orbital radiotherapy (118, 119). However, in view of the evidence that i.v. glucocorticoids are more effective and better tolerated than oral glucocorticoids (1) and that i.v. glucocorticoids combined with orbital radiotherapy are more effective than oral glucocorticoids combined with orbital radiotherapy (83), we suggest that orbital radiotherapy combined with i.v. glucocorticoids can be considered a second-line therapy (expert opinion), particularly in patients with eye muscle dysfunction, although a prospective RCT

**Figure 3**

Algorithm for the second-line management of moderate-to-severe and active Graves' orbitopathy. There are currently six alternative second-line treatments ('six pathways') for persistent moderate-to-severe and active GO as a non-response to a first-line treatment: (i) the second cycle of iv methylprednisolone (starting with 0.75 g per infusion per week, allowed is a cumulative dose of 8 g per cycle) and subsequent to careful ophthalmic and biochemical (liver enzymes) evaluation; (ii) oral glucocorticoids with either cyclosporine or azathioprine; (iii) orbital radiotherapy with either oral or i.v. glucocorticoids; (iv) teprotumumab (availability and affordability pending); (v) rituximab (not in patients at risk for optic neuropathy); (vi) tocilizumab (considered in glucocorticoid-resistant patients). Head-to-head comparison data are available for rituximab against iv methylprednisolone (145). Overall and based on the features of GO that they are most likely to be effective for i.v. glucocorticoids, mycophenolate, tocilizumab, rituximab, and cyclosporine substantially decreased inflammatory ophthalmic signs while orbital radiotherapy (preferably in combination with glucocorticoids) significantly improved eye muscle motility and/or diplopia. In comparison, Teprotumumab showed the strongest effect on exophthalmos. Of note, with the exception of teprotumumab (FDA cleared for the treatment of active and moderately severe GO in January 2020), all drugs stated in Figs 2 and/or 3 can be given as off-label treatment. GO, Graves' orbitopathy; GD, Graves' disease.

directly comparing i.v. glucocorticoid monotherapy vs i.v. glucocorticoids combined with orbital radiotherapy is not available and an evidence-based recommendation for a single glucocorticoid dosage is missing.

Rituximab can be recommended as second-line treatment at the dosage reported in one RCT (one 500 mg shot) (145) or at lower dose (one 100 mg shot) (145), however not in patients with a potential risk for DON (144, 145). Rituximab is the only drug with a head-to-head

comparison of i.v. glucocorticoids (145). Tocilizumab may also be considered in glucocorticoid-resistant patients, though robust data concerning efficacy and safety are still missing. Finally, Teprotumumab, as a promising and effective drug for GO (136, 137), is currently available in the US only. Subsequent to its clearance by the European Medicine Agency, publication of long-term efficacy and safety data, information on need for post-teprotumumab rehabilitative surgery, and, optimally, subsequent to head-

to-head comparison with i.v. glucocorticoids within a future RCT, teprotumumab will likely play a relevant role in the management of patients with moderate-to severe and active GO provided it is available and affordable to each patient (Recommendations #22–25).

Overall and based on the features of GO that they are most likely to be effective for i.v. glucocorticoids, mycophenolate, tocilizumab, rituximab, and cyclosporine substantially decreased inflammatory ophthalmic signs while orbital radiotherapy (preferably in combination with glucocorticoids) significantly improved eye muscle motility and/or diplopia. In comparison, teprotumumab showed the strongest effect on exophthalmos.

## Management of sight-threatening GO

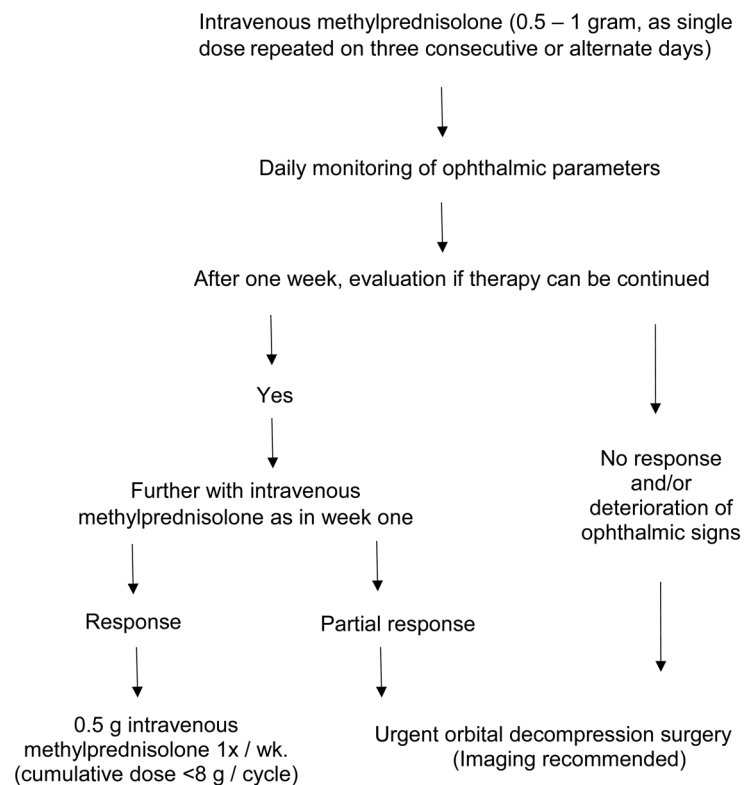
Sight-threatening GO is an emergency that is treated immediately. Impairment or loss of vision can be due to DON, severe corneal exposure breakdown, and, in rare cases, eyeball subluxation causing acute optic neuropathy due to stretching of the optic nerve, increase in the intraocular pressure, and/or corneal breakdown. A small RCT (165) showed that in DON patients immediate decompression did not result in a better outcome compared to i.v. glucocorticoids given as first-line treatment. In a retrospective study of 24 DON patients (40 eyes), more than 40% of patients showed permanent restoration of normal

### SIGHT - THREATENING GO (Optic Neuropathy)

#### General recommendations

- Immediate referral to thyroid-eye clinic
- Stop smoking
- Avoid radioactive iodine treatment
- Stabilize thyroid dysfunction with antithyroid drugs
- Avoid iatrogenic hypothyroidism in treating patients with GD/GO

#### Specific Management



**Figure 4**

Algorithm for the management of sight-threatening Graves' orbitopathy. The first-line treatment for optic neuropathy is high-dose iv methylprednisolone (single doses of 500 to 1000 mg) for three consecutive days or most preferably and for safety reasons on every second day (alternate days) during the first week, which can be repeated for another week. When the response is absent or poor with a deterioration in visual acuity or visual fields, urgent orbital decompression surgery is mandatory. GO, Graves' orbitopathy; GD, Graves' disease.



visual function after high-dose i.v. methylprednisolone therapy (88). Based on these results, the first-line treatment of DON is high-dose (single doses of 500 to 1000 mg) i.v. methylprednisolone for three consecutive days or more preferably (for safety reasons) (86, 90) on every second day (alternate days) during the first week, which can be repeated for another week (Fig. 4). When the response is absent or poor with a deterioration in visual acuity or visual fields, urgent orbital decompression surgery is mandatory. Blepharorrhaphy, tarsorrhaphy, lid lengthening, extraocular muscle recession, gluing, antibiotics, and transplantation are used to protect the cornea when severe corneal exposure (ulceration) or corneal breakdown occurs. Subluxation of the eyeball is treated with orbital decompression (Recommendations #26–27).

### Orbital/ophthalmic surgery in the treatment of GO

In the active phase of GO, decompression surgery is indicated in patients with severe exposure keratopathy and, as second-line treatment, in patients with DON not responding to i.v. glucocorticoids. Local treatment (tarsorrhaphies, corneal patches, or gluing) can be used in the same phase as temporary measures to shield the cornea for superficial damages or to correct extreme corneal thinning, thus decreasing risks of spontaneous eyeball perforation or perforation in the course of subsequent decompression surgery. In the post-inflammatory, inactive phase, residual disfigurements (exophthalmos, lid retractions, eyelid, and periorbital puffiness, strabismus, and correlated symptoms such eye grittiness, retro/peri-ocular tension, and diplopia) can be treated by a combination of decompression, ophthalmic plastic, and strabismus surgery (166).

### Treatment of hyperthyroidism in patients with GO (Recommendations #28–32)

Graves' hyperthyroidism can be managed by thionamide antithyroid drugs (ATDs), RAI treatment, or, less frequently, total thyroidectomy (Tx) (42, 167). ATDs and Tx *per se* do not modify the natural history of mild GO (53, 54, 168), although RCTs on moderate-to-severe GO are lacking. Long-term ATD treatment is beneficial for GO due to the normalization of thyroid function and the associated decline of TSHR-Ab serum levels (169), which are a biomarker for GO (43, 170). Avoiding

iatrogenic hypothyroidism in treating patients with GD/GO (Figs 1, 2, 3 and 4) is an important principle of medical management. With this respect, within a large EUGOGO prospective multicenter observational cohort study of 344 patients with Graves' hyperthyroidism, the prevalence of biochemical euthyroidism during treatment with ATDs was higher during the ATD titration regimen compared to the 'block and replace' regimen. *De novo* development of GO did not differ significantly between the two regimens (171).

A small RCT (172) and a retrospective case study (173) showed that early Tx may be associated with a better outcome of immunosuppressive treatment for moderate-to-severe and active GO. At variance, RAI treatment is associated with a definite risk for GO, which can be prevented, in patients at risk, by oral low-dose and short-term prednisone prophylaxis, given concomitantly with RAI treatment, and prompt correction of post-RAI hypothyroidism. Total thyroid ablation (i.e. Tx followed by RAI ablation of thyroid remnants) has been proposed, and two RCTs have shown a beneficial effect of this procedure following i.v. glucocorticoid treatment in patients with moderate-to-severe and active GO, in the short, but not in the long term (174, 175, 176).

The optimal treatment for hyperthyroidism in patients with GO is an unsolved dilemma, and there is no current evidence as to the superiority of the conservative approach (ATDs) with respect to the ablative approach (Tx, RAI, total thyroid ablation) or *vice versa* (177). If GO, either mild or moderate-to-severe is stably and longstanding inactive, any treatment for hyperthyroidism can be selected, based on standardized criteria and patient preference after extensive counseling (167), as it is unlikely to cause recurrence or progression of GO (37, 178). In patients with residual, but long-standing inactive moderate-to-severe GO, oral glucocorticoid prophylaxis can be considered if RAI treatment is selected and risk factors are still present. If GO is active and mild, ATD treatment (or Tx) is mostly preferred. RAI treatment can be used in combination with oral prednisone/prednisolone prophylaxis (167). When GO is moderate-to-severe and active, management of GO should be prioritized, because delayed treatment is associated with a lower response rate (8). While GO is being treated, hyperthyroidism is controlled by ATDs, possibly given longer than the usual 18–24 months (178, 179). Large thyroid glands (>50 mL) and/or nodular goiters can be surgically treated if mechanical signs of tracheal compression or suspicion of thyroid cancer are present. When GO is sight threatening, its emergency treatment either medical and/or surgical is an absolute priority;

hyperthyroidism is stabilized by ATDs until treatment of GO is completed (8).

## Management of GO during viral pandemic

Patients with mild GO should receive the usual local treatment (Fig. 1) and should be urged to quit smoking to prevent progression of GO (180). As to moderate-to-severe and active GO, glucocorticoids and other immunosuppressive agents could make patients more susceptible to infections (1). Discontinuation of long-term glucocorticoid treatment may be associated with adrenal failure, which, in turn, increases the risk of developing infections and related mortality, likely including COVID-19 (181). Nevertheless, unless immunized or having had COVID, all of us have no immunity to COVID, so adding immunosuppression will not increase that risk. Furthermore, dexamethasone or methylprednisolone or tocilizumab has now become the standard of care for COVID (182, 183). Also, it is now clear that very high-dose steroids used in COVID does not cause adrenal suppression, and normal adrenal function was observed in patients who survived COVID-19 Infection (184). In line with this, withdrawal of i.v. glucocorticoid treatment in GO patients is not associated with adrenal failure (185, 186).

No studies are available on the use of i.v. glucocorticoids or other immunosuppressive agents for GO during the current pandemic. With ongoing vaccination of the population, the risk related to immunosuppression will gradually decrease. Although the impact of immunomodulatory/immunosuppressive therapies on the efficacy of vaccination against COVID is not known, and steroids are known to decrease the efficacy of other vaccines, it seems reasonable to propose that patients already under treatment continue i.v. glucocorticoids or other immunosuppressive treatments under careful monitoring (180). Oral treatments can be continued at home, strictly following rules of social distancing, shielding, and hygiene. Sight-threatening GO is an emergency and should be treated as such, irrespective of a viral pandemic.

## Conclusions and perspectives

It is reasonable to recommend the combination of i.v. methylprednisolone and mycophenolate (sodium) as the updated standard of care in moderate-to-severe and active GO, in view of its practicability and superior

efficacy to weekly i.v. glucocorticoid monotherapy. Biologicals, especially teprotumumab and, to a lesser degree, tocilizumab or rituximab, hold great promise in the future management of GO and can be useful if patients are intolerant or resistant to standard immunosuppressive treatment. However, they were not rigorously tested in large RCTs against the current standard of care, namely, i.v. glucocorticoids. The fact that they may not be widely available or affordable, as well as the lack of information, say, on the need for subsequent rehabilitative surgery, further add to their current limitations. As multiple pathogenic pathways are implicated in GO, several targeted therapies are worth exploring in clinical trials, for example, monoclonal antibodies and/or small molecules targeting the TSHR (187, 188) or the CD40 molecule expressed in both thyrocytes and orbital fibroblasts (189), or anti-IL-23/anti-IL-17 for the IL-23/IL-17 axis and sirolimus for the mTOR pathway (190). Worthwhile is also a modulating impact on the microbiome in patients with GO (191). Overall, any novel therapeutic strategy in GO must be examined in RCTs, hopefully adopting the same assessment of treatment primary outcomes, before any conclusion regarding efficacy (i.e. proptosis and diplopia) and safety can be drawn.

### Declaration of interest

Luigi Bartalena: nothing to disclose. George J Kahaly: The Johannes Gutenberg University (JGU) Medical Center, Mainz, Germany has received research-associated funding from the JGU Medical Faculty, AdvanceCor (Germany), Apitope (Belgium), Berlin-Chemie (Germany), Byondis (The Netherlands), Horizon (USA), Immunovant (USA), ISAR (Germany), Mediomics (USA), Merck (Germany), Novartis (USA), Quidel (USA), River Vision (USA), and Roche (Switzerland). G J K consults for GlycoEra (Switzerland), Immunovant, Mediomics, Merck, Novartis, Quidel, & VasaraGen (USA). Lelio Baldeschi: nothing to disclose. Colin Dayan: payment for lectures from Berlin-Chemie and Sanofi-Aventis. Anja Eckstein: took part in multicenter studies from Horizon, Immunovant and Novartis. Lecture honoraria from Sanofi Aventis and Novo Nordisk. Claudio Marocchi: consultant for Horizon Pharma, his institution received research funding for performing Teprotumumab study 2 (NCT03298867). Michele Marinò: his institution received research funding from Horizon Pharma for performing Teprotumumab studies OPTIC and OPTIC-X (EudraCT 2017-002763-18/EudraCT 2017-002713-58). Bijay Vaidya: Lecture Honoraria from Berlin-Chemie. Wilmar Wiersinga: consultant for Riverside, Horizon and Immunovant.

### Funding

This work did not receive any specific grant from any funding agency in the public, commercial, or not-for-profit sector.

### Acknowledgements

The following is the list of 48 EUGOGO members listed as collaborators/contributors to this guideline manuscript. Ankara (Turkey): Goksun Ayvaz, Onur Konuk; Belgrade (Serbia): Jasmina Ciric, Bijliana Beleslin; Brussels

(Belgium): Antonella Boschi, Maria Cristina Burlacu; Cardiff (UK): Dan Morris; Catania (Italy): Rosario Le Moli, Antonio Marino; Edinburgh (UK): Justin McKee, Nicola Zammit; Essen (Germany): Dagmar Führer; Exeter (UK): Ioana Pereni; Göttingen: Michael Schittkowski, Dirk Raddatz; London (UK): Vickie Lee, Karim Meeran; Lyon (France): Juliette Abeillon, Thia Soui Thong; Mainz: Katharina Ponto; Milan (Italy): Ilaria Muller, Nicola Currò; München (Germany): Christoph Hintschich, Roland Gärtner; Newcastle (UK): Simon Pearce, Lucy Clarke; Odense (Denmark): Thomas Brix, Dorte Bechtold; Olten (Switzerland): Gottfried Rudovfsky, Nicole Fichter; Paris (France): Laurence Du Pasquier, Julia Meney; Pisa (Italy): Francesca Menconi, Giulia Lanzolla; Singapore: Gangadhara Sundar, Samantha Peiling Yung; Thessaloniki (Greece): Kostas Boboridis, Panagiotis Anagnostis; Valencia (Spain): Marta Pérez Lopez, Carlos Javier Sanchez; Varese (Italy): Maria Laura Tanda, Simone Donati; Vienna (Austria): Andrea Papp, Shuren Li; Warsaw (Poland): Anna Jablonska, Piotr Miskiewicz; Zagreb (Croatia): Jelena Juri Mandic, Maja Baretic.

Lara Frommer, MSc and Jan Längericht (pharmacist), both JGU Thyroid Lab, Mainz, Germany are acknowledged for their editorial assistance.

## References

- Kahaly GJ. Management of Graves thyroidal and extrathyroidal disease: an update. *Journal of Clinical Endocrinology and Metabolism* 2020 **105** 3704–3720. (<https://doi.org/10.1210/clinem/dgaa646>)
- Perros P, Zarkovic M, Azzolini C, Ayvaz G, Baldeschi L, Bartalena L, Boschi A, Bournaud C, Brix TH, Covelli D *et al.* PREGO (presentation of Graves' orbitopathy) study: changes in referral patterns to European Group on Graves' orbitopathy (EUGOGO) centres over the period from 2000 to 2012. *British Journal of Ophthalmology* 2015 **99** 1531–1535. (<https://doi.org/10.1136/bjophthalmol-2015-306733>)
- Bartalena L, Piantanida E, Gallo D, Lai A & Tanda ML. Epidemiology, natural history, risk factors, and prevention of Graves' orbitopathy. *Frontiers in Endocrinology* 2020 **11** 615993. (<https://doi.org/10.3389/fendo.2020.615993>)
- Kahaly GJ, Petrak F, Hardt J, Pitz S & Egle UT. Psychosocial morbidity of Graves' orbitopathy. *Clinical Endocrinology* 2005 **63** 395–402. (<https://doi.org/10.1111/j.1365-2265.2005.02352.x>)
- Wiersinga WM. Quality of life in Graves' ophthalmopathy. *Best Practice and Research: Clinical Endocrinology and Metabolism* 2012 **26** 359–370. (<https://doi.org/10.1016/j.beem.2011.11.001>)
- Ponto KA, Hommel G, Pitz S, Elflein H, Pfeiffer N & Kahaly GJ. Quality of life in a German Graves orbitopathy population. *American Journal of Ophthalmology* 2011 **152** 483.e1–490.e1. (<https://doi.org/10.1016/j.ajo.2011.02.018>)
- Ponto KA, Merkesdal S, Hommel G, Pitz S, Pfeiffer N & Kahaly GJ. Public health relevance of Graves' orbitopathy. *Journal of Clinical Endocrinology and Metabolism* 2013 **98** 145–152. (<https://doi.org/10.1210/jc.2012-3119>)
- Bartalena L, Baldeschi L, Boboridis K, Eckstein A, Kahaly GJ, Marcocci C, Perros P, Salvi M, Wiersinga WM & European Group on Graves. The 2016 European Thyroid Association/European Group on Graves' Orbitopathy Guidelines for the Management of Graves' Orbitopathy. *European Thyroid Journal* 2016 **5** 9–26. (<https://doi.org/10.1159/000443828>)
- Wiersinga WM. Advances in treatment of active, moderate-to-severe Graves' ophthalmopathy. *Lancet: Diabetes and Endocrinology* 2017 **5** 134–142. ([https://doi.org/10.1016/S2213-8587\(16\)30046-8](https://doi.org/10.1016/S2213-8587(16)30046-8))
- Smith TJ & Bartalena L. Will biological agents supplant systemic glucocorticoids as the first-line treatment for thyroid-associated ophthalmopathy? *European Journal of Endocrinology* 2019 **181** D27–D43. (<https://doi.org/10.1530/EJE-19-0389>)
- Davies TF, Andersen S, Latif R, Nagayama Y, Barbesino G, Brito M, Eckstein AK, Stagnaro-Green A & Kahaly GJ. Graves' disease. *Nature Reviews: Disease Primers* 2020 **6** 52. (<https://doi.org/10.1038/s41572-020-0184-y>)
- Taylor PN, Zhang L, Lee RWJ, Muller I, Ezra DG, Dayan CM, Kahaly GJ & Ludgate M. New insights into the pathogenesis and nonsurgical management of Graves orbitopathy. *Nature Reviews: Endocrinology* 2020 **16** 104–116. (<https://doi.org/10.1038/s41574-019-0305-4>)
- Swiglo BA, Murad MH, Schunemann HJ, Kunz R, Vigersky RA, Guyatt GH & Montori VM. A case for clarity, consistency, and helpfulness: state-of-the-art clinical practice guidelines in endocrinology using the grading of recommendations, assessment, development, and evaluation system. *Journal of Clinical Endocrinology and Metabolism* 2008 **93** 666–673. (<https://doi.org/10.1210/jc.2007-1907>)
- European Group on Graves, Wiersinga WM, Perros P, Kahaly GJ, Mourits MP, Baldeschi L, Boboridis K, Boschi A, Dickinson AJ, Kendall-Taylor P *et al.* Clinical assessment of patients with Graves' orbitopathy: the European Group on Graves' Orbitopathy recommendations to generalists, specialists and clinical researchers. *European Journal of Endocrinology* 2006 **155** 387–389. (<https://doi.org/10.1530/eje.1.02230>)
- Terwee CB, Prummel MF, Gerding MN, Kahaly GJ, Dekker FW & Wiersinga WM. Measuring disease activity to predict therapeutic outcome in Graves' ophthalmopathy. *Clinical Endocrinology* 2005 **62** 145–155. (<https://doi.org/10.1111/j.1365-2265.2005.02186.x>)
- Mourits MP, Koornneef L, Wiersinga WM, Prummel MF, Berghout A & van der Gaag R. Clinical criteria for the assessment of disease activity in Graves' ophthalmopathy: a novel approach. *British Journal of Ophthalmology* 1989 **73** 639–644. (<https://doi.org/10.1136/bjo.73.8.639>)
- Dickinson AJ & Perros P. Controversies in the clinical evaluation of active thyroid-associated orbitopathy: use of a detailed protocol with comparative photographs for objective assessment. *Clinical Endocrinology* 2001 **55** 283–303. (<https://doi.org/10.1046/j.1365-2265.2001.01349.x>)
- Dolman PJ & Rootman J. VISA classification for Graves orbitopathy. *Ophthalmic Plastic and Reconstructive Surgery* 2006 **22** 319–324. (<https://doi.org/10.1097/OI.iop.0000235499.34867.85>)
- Kahaly GJ. Imaging in thyroid-associated orbitopathy. *European Journal of Endocrinology* 2001 **145** 107–118. (<https://doi.org/10.1530/eje.0.1450107>)
- Muller-Forell W & Kahaly GJ. Neuroimaging of Graves' orbitopathy. *Best Practice and Research: Clinical Endocrinology and Metabolism* 2012 **26** 259–271. (<https://doi.org/10.1016/j.beem.2011.11.009>)
- Jain AP, Gellada N, Ugradar S, Kumar A, Kahaly G & Douglas R. Teprotumumab reduces extraocular muscle and orbital fat volume in thyroid eye disease. *British Journal of Ophthalmology* 2020 In press. (<https://doi.org/10.1136/bjophthalmol-2020-317806>)
- Bartalena L, Baldeschi L, Dickinson A, Eckstein A, Kendall-Taylor P, Marcocci C, Mourits M, Perros P, Boboridis K, Boschi A *et al.* Consensus statement of the European Group on Graves' orbitopathy (EUGOGO) on management of GO. *European Journal of Endocrinology* 2008 **158** 273–285. (<https://doi.org/10.1530/EJE-07-0666>)
- Werner SC. Modification of the classification of the eye changes of Graves' disease. *American Journal of Ophthalmology* 1977 **83** 725–727. ([https://doi.org/10.1016/0002-9394\(77\)90140-4](https://doi.org/10.1016/0002-9394(77)90140-4))
- Eckstein AK, Plicht M, Lax H, Hirche H, Quadbeck B, Mann K, Steuhl KP, Esser J & Morgenthaler NG. Clinical results of anti-inflammatory therapy in Graves' ophthalmopathy and association with thyroidal autoantibodies. *Clinical Endocrinology* 2004 **61** 612–618. (<https://doi.org/10.1111/j.1365-2265.2004.02143.x>)
- Wiersinga WM, Prummel MF, Mourits MP, Koornneef L & Buller HR. Classification of the eye changes of Graves' disease. *Thyroid* 1991 **1** 357–360. (<https://doi.org/10.1089/thy.1991.1.357>)
- Tanda ML, Piantanida E, Liparulo L, Veronesi G, Lai A, Sassi L, Pariani N, Gallo D, Azzolini C, Ferrario M *et al.* Prevalence and natural history of Graves' orbitopathy in a large series of patients with newly diagnosed Graves' hyperthyroidism seen at a single center. *Journal of*

- Clinical Endocrinology and Metabolism* 2013 **98** 1443–1449. (<https://doi.org/10.1210/jc.2012-3873>)
- 27 Ippolito S, Cusini C, Lasalvia P, Gianfagna F, Veronesi G, Gallo D, Masiello E, Premoli P, Sabatino J, Mercuriali A *et al.* Change in newly diagnosed Graves' disease phenotype between the twentieth and the twenty-first centuries: meta-analysis and meta-regression. *Journal of Endocrinological Investigation* 2021 **44** 1707–1718. (<https://doi.org/10.1007/s40618-020-01479-z>)
- 28 Wiersinga W, Zarkovic M, Bartalena L, Donati S, Perros P, Okosieme O, Morris D, Fichter N, Lareida J, von Arx G *et al.* Predictive score for the development or progression of Graves' orbitopathy in patients with newly diagnosed Graves' hyperthyroidism. *European Journal of Endocrinology* 2018 **178** 635–643. (<https://doi.org/10.1530/EJE-18-0039>)
- 29 Kahaly GJ, Wüster C, Olivo PD & Diana T. High titers of thyrotropin receptor antibodies are associated with orbitopathy in patients with Graves disease. *Journal of Clinical Endocrinology and Metabolism* 2019 **104** 2561–2568. (<https://doi.org/10.1210/jc.2018-02705>)
- 30 Perros P, Dayan CM, Dickinson AJ, Ezra D, Estcourt S, Foley P, Hickey J, Lazarus JH, MacEwen CJ, McLaren J *et al.* Management of patients with Graves' orbitopathy: initial assessment, management outside specialised centres and referral pathways. *Clinical Medicine* 2015 **15** 173–178. (<https://doi.org/10.7861/clinmedicine.15-2-173>)
- 31 Baretic M, Juri MJ, Kusacic KS, Gudelj L, Radic M & Zlatar M. Awareness of EUGOGO guidelines and attitudes regarding smoking in Graves' orbitopathy in Croatia. *Taiwan Journal of Ophthalmology* 2021 In press. ([https://doi.org/10.4103/tjo.tjo\\_2\\_21](https://doi.org/10.4103/tjo.tjo_2_21))
- 32 Estcourt S, Hickey J, Perros P, Dayan C & Vaidya B. The patient experience of services for thyroid eye disease in the United Kingdom: results of a nationwide survey. *European Journal of Endocrinology* 2009 **161** 483–487. (<https://doi.org/10.1530/EJE-09-0383>)
- 33 Terwee CB, Dekker FW, Mourits MP, Gerding MN, Baldeschi L, Kalmann R, Prummel MF & Wiersinga WM. Interpretation and validity of changes in scores on the Graves' ophthalmopathy quality of life questionnaire (GO-QOL) after different treatments. *Clinical Endocrinology* 2001 **54** 391–398. (<https://doi.org/10.1046/j.1365-2265.2001.01241.x>)
- 34 Bartalena L & Wiersinga WM. Proposal for standardization of primary and secondary outcomes in patients with active, moderate-to-severe Graves' orbitopathy. *European Thyroid Journal* 2020 **9** (Supplement 1) 3–16. (<https://doi.org/10.1159/000510700>)
- 35 Prummel MF, Wiersinga W, Mourits M, Koornneef L, Berghout A & van der Gaag R. Amelioration of eye changes of Graves' ophthalmopathy by achieving euthyroidism. *Acta Endocrinologica* 1989 **121** 185–190.
- 36 Prummel MF, Wiersinga WM, Mourits MP, Koornneef L, Berghout A & van der Gaag R. Effect of abnormal thyroid function on the severity of Graves' ophthalmopathy. *Archives of Internal Medicine* 1990 **150** 1098–1101.
- 37 Perros P, Kendall-Taylor P, Neoh C, Frewin S & Dickinson J. A prospective study of the effects of radioiodine therapy for hyperthyroidism in patients with minimally active Graves' ophthalmopathy. *Journal of Clinical Endocrinology and Metabolism* 2005 **90** 5321–5323. (<https://doi.org/10.1210/jc.2005-0507>)
- 38 Diana T, Ungerer M, Wüster C, Fassbender J, Li Z, Reimann A, Holthoff HP, Kanitz M & Kahaly GJ. A cyclic peptide significantly improves thyroid function, thyrotropin-receptor antibodies and orbital mucine/collagen content in a long-term Graves' disease mouse model. *Journal of Autoimmunity* 2021 **122** 102666. (<https://doi.org/10.1016/j.jaut.2021.102666>)
- 39 Hai YP, Lee ACH, Frommer L, Diana T & Kahaly GJ. Immunohistochemical analysis of human orbital tissue in Graves' orbitopathy. *Journal of Endocrinological Investigation* 2020 **43** 123–137. (<https://doi.org/10.1007/s40618-019-01116-4>)
- 40 Diana T, Brown RS, Bossowski A, Segni M, Niedziela M, König J, Bossowska A, Ziara K, Hale A, Smith J *et al.* Clinical relevance of thyroid-stimulating autoantibodies in pediatric Graves' disease – a multicenter study. *Journal of Clinical Endocrinology and Metabolism* 2014 **99** 1648–1655. (<https://doi.org/10.1210/jc.2013-4026>)
- 41 Kahaly GJ, Diana T, Glang J, Kanitz M, Pitz S & König J. Thyroid stimulating antibodies are highly prevalent in Hashimoto's thyroiditis and associated orbitopathy. *Journal of Clinical Endocrinology and Metabolism* 2016 **101** 1998–2004. (<https://doi.org/10.1210/jc.2016-1220>)
- 42 Kahaly GJ, Diana T, Kanitz M, Frommer L & Olivo PD. Prospective trial of functional thyrotropin receptor antibodies in Graves disease. *Journal of Clinical Endocrinology and Metabolism* 2020 **105** e1006–e1014. (<https://doi.org/10.1210/clinem/dg292>)
- 43 George A, Diana T, Langericht J & Kahaly GJ. Stimulatory thyrotropin receptor antibodies are a biomarker for Graves' orbitopathy. *Frontiers in Endocrinology* 2020 **11** 629925. (<https://doi.org/10.3389/fendo.2020.629925>)
- 44 Leschik JJ, Diana T, Olivo PD, König J, Krahn U, Li Y, Kanitz M & Kahaly GJ. Analytical performance and clinical utility of a bioassay for thyroid-stimulating immunoglobulins. *American Journal of Clinical Pathology* 2013 **139** 192–200. (<https://doi.org/10.1309/AJCPZUT7CNUEU7OP>)
- 45 Wiersinga WM. Smoking and thyroid. *Clinical Endocrinology* 2013 **79** 145–151. (<https://doi.org/10.1111/cen.12222>)
- 46 Khong JJ, Finch S, De Silva C, Rylander S, Craig JE, Selva D & Ebeling PR. Risk factors for Graves' orbitopathy; the Australian thyroid-associated orbitopathy research (ATOR) study. *Journal of Clinical Endocrinology and Metabolism* 2016 **101** 2711–2720. (<https://doi.org/10.1210/jc.2015-4294>)
- 47 Bartalena L, Marcocci C, Tanda ML, Manetti L, Dell'Unto E, Bartolomei MP, Nardi M, Martino E & Pinchera A. Cigarette smoking and treatment outcomes in Graves ophthalmopathy. *Annals of Internal Medicine* 1998 **129** 632–635. (<https://doi.org/10.7326/0003-4819-129-8-199810150-00010>)
- 48 Traisk F, Tallstedt L, Abraham-Nordling M, Andersson T, Berg G, Calissendorff J, Hallengren B, Hedner P, Lantz M, Nystrom E *et al.* Thyroid-associated ophthalmopathy after treatment for Graves' hyperthyroidism with antithyroid drugs or iodine-131. *Journal of Clinical Endocrinology and Metabolism* 2009 **94** 3700–3707. (<https://doi.org/10.1210/jc.2009-0747>)
- 49 Eckstein A, Quadbeck B, Mueller G, Rettenmeier AW, Hoermann R, Mann K, Steuhl P & Esser J. Impact of smoking on the response to treatment of thyroid associated ophthalmopathy. *British Journal of Ophthalmology* 2003 **87** 773–776. (<https://doi.org/10.1136/bjo.87.6.773>)
- 50 Matheis N, Lantz M, Grus FH, Ponto KA, Wolters D, Brorson H, Planck T, Shahida B, Pitz S, Pfeiffer N *et al.* Proteomics of orbital tissue in thyroid-associated orbitopathy. *Journal of Clinical Endocrinology and Metabolism* 2015 **100** E1523–E1530. (<https://doi.org/10.1210/jc.2015-2976>)
- 51 Pfeilschifter J & Ziegler R. Smoking and endocrine ophthalmopathy: impact of smoking severity and current vs lifetime cigarette consumption. *Clinical Endocrinology* 1996 **45** 477–481. (<https://doi.org/10.1046/j.1365-2265.1996.8220832.x>)
- 52 Bartalena L, Marcocci C, Bogazzi F, Panicucci M, Lepri A & Pinchera A. Use of corticosteroids to prevent progression of Graves' ophthalmopathy after radioiodine therapy for hyperthyroidism. *New England Journal of Medicine* 1989 **321** 1349–1352. (<https://doi.org/10.1056/NEJM198911163212001>)
- 53 Tallstedt L, Lundell G, Torring O, Wallin G, Ljunggren JG, Blomgren H & Taube A. Occurrence of ophthalmopathy after treatment for Graves' hyperthyroidism. The Thyroid Study Group. *New England Journal of Medicine* 1992 **326** 1733–1738. (<https://doi.org/10.1056/NEJM199206253262603>)
- 54 Bartalena L, Marcocci C, Bogazzi F, Manetti L, Tanda ML, Dell'Unto E, Bruno-Bossio G, Nardi M, Bartolomei MP, Lepri A *et al.* Relation between therapy for hyperthyroidism and the course of Graves' ophthalmopathy. *New England Journal of Medicine* 1998 **338** 73–78. (<https://doi.org/10.1056/NEJM199801083380201>)

- 55 Ponto KA, Zang S & Kahaly GJ. The tale of radioiodine and Graves' orbitopathy. *Thyroid* 2010 **20** 785–793. (<https://doi.org/10.1089/thy.2010.1640>)
- 56 Vannucchi G, Covelli D, Campi I, Curro N, Dazzi D, Rodari M, Pepe G, Chiti A, Guastella C, Lazzaroni E *et al.* Prevention of orbitopathy by oral or intravenous steroid prophylaxis in short duration Graves' disease patients undergoing radioiodine ablation: a prospective randomized control trial study. *Thyroid* 2019 **29** 1828–1833. (<https://doi.org/10.1089/thy.2019.0150>)
- 57 Shiber S, Stiebel-Kalish H, Shimon I, Grossman A & Robenshtok E. Glucocorticoid regimens for prevention of Graves' ophthalmopathy progression following radioiodine treatment: systematic review and meta-analysis. *Thyroid* 2014 **24** 1515–1523. (<https://doi.org/10.1089/thy.2014.0218>)
- 58 Lai A, Sassi L, Compri E, Marino F, Sivelli P, Piantanida E, Tanda ML & Bartalena L. Lower dose prednisone prevents radioiodine-associated exacerbation of initially mild or absent Graves' orbitopathy: a retrospective cohort study. *Journal of Clinical Endocrinology and Metabolism* 2010 **95** 1333–1337. (<https://doi.org/10.1210/jc.2009-2130>)
- 59 Rosetti S, Tanda ML, Veronesi G, Masiello E, Premoli P, Gallo D, Cusini C, Donati S, Sabatino J, Ippolito S *et al.* Oral steroid prophylaxis for Graves' orbitopathy after radioactive iodine treatment for Graves' disease is not only effective, but also safe. *Journal of Endocrinological Investigation* 2020 **43** 381–383. (<https://doi.org/10.1007/s40618-019-01126-2>)
- 60 Lanzolla G, Vannucchi G, Ionni I, Campi I, Sileo F, Lazzaroni E & Marino M. Cholesterol serum levels and use of statins in Graves' orbitopathy: a new starting point for the therapy. *Frontiers in Endocrinology* 2019 **10** 933. (<https://doi.org/10.3389/fendo.2019.00933>)
- 61 Stein JD, Childers D, Gupta S, Talwar N, Nan B, Lee BJ, Smith TJ & Douglas R. Risk factors for developing thyroid-associated ophthalmopathy among individuals with Graves disease. *JAMA Ophthalmology* 2015 **133** 290–296. (<https://doi.org/10.1001/jamaophthalmol.2014.5103>)
- 62 Nilsson A, Tsoumani K & Planck T. Statins decrease the risk of orbitopathy in newly diagnosed patients with Graves' disease. *Journal of Clinical Endocrinology and Metabolism* 2021 **106** 1325–1332. (<https://doi.org/10.1210/clinem/dgab070>)
- 63 Sabini E, Mazzi B, Profilo MA, Mautone T, Casini G, Rocchi R, Ionni I, Menconi F, Leo M, Nardi M *et al.* High serum cholesterol is a novel risk factor for Graves' orbitopathy: results of a cross-sectional study. *Thyroid* 2018 **28** 386–394. (<https://doi.org/10.1089/thy.2017.0430>)
- 64 Lanzolla G, Sabini E, Profilo MA, Mazzi B, Sframeli A, Rocchi R, Menconi F, Leo M, Nardi M, Vitti P *et al.* Relationship between serum cholesterol and Graves' orbitopathy (GO): a confirmatory study. *Journal of Endocrinological Investigation* 2018 **41** 1417–1423. (<https://doi.org/10.1007/s40618-018-0915-z>)
- 65 Naselli A, Moretti D, Regalbuto C, Arpi ML, Lo Giudice F, Frasca F, Belfiore A & Le Moli R. Evidence that baseline levels of low-density lipoproteins cholesterol affect the clinical response of Graves' ophthalmopathy to parenteral corticosteroids. *Frontiers in Endocrinology* 2020 **11** 609895. (<https://doi.org/10.3389/fendo.2020.609895>)
- 66 Gurdal C, Sarac O, Genc I, Kirimlioglu H, Takmaz T & Can I. Ocular surface and dry eye in Graves' disease. *Current Eye Research* 2011 **36** 8–13. (<https://doi.org/10.3109/02713683.2010.526285>)
- 67 Gupta A, Sadeghi PB & Akpek EK. Occult thyroid eye disease in patients presenting with dry eye symptoms. *American Journal of Ophthalmology* 2009 **147** 919–923. (<https://doi.org/10.1016/j.ajo.2008.12.007>)
- 68 Matheis N, Grus FH, Breitenfeld M, Knych I, Funke S, Pitz S, Ponto KA, Pfeiffer N & Kahaly GJ. Proteomics differentiate between thyroid-associated orbitopathy and dry eye syndrome. *Investigative Ophthalmology and Visual Science* 2015 **56** 2649–2656. (<https://doi.org/10.1167/iovs.15-16699>)
- 69 Selter JH, Gire AI & Sikder S. The relationship between Graves' ophthalmopathy and dry eye syndrome. *Clinical Ophthalmology* 2015 **9** 57–62. (<https://doi.org/10.2147/OPHT.S76583>)
- 70 Ismailova DS, Fedorov AA & Grusha YO. Ocular surface changes in thyroid eye disease. *Orbit* 2013 **32** 87–90. (<https://doi.org/10.3109/01676830.2013.764440>)
- 71 Eckstein AK, Finkenrath A, Heiligenhaus A, Renzing-Kohler K, Esser J, Kruger C, Quadbeck B, Steuhl KP & Gieseler RK. Dry eye syndrome in thyroid-associated ophthalmopathy: lacrimal expression of TSH receptor suggests involvement of TSHR-specific autoantibodies. *Acta Ophthalmologica Scandinavica* 2004 **82** 291–297. (<https://doi.org/10.1111/j.1395-3907.2004.00268.x>)
- 72 Vogel R, Crockett RS, Oden N, Laliberte TW, Molina L & Sodium Hyaluronate Ophthalmic Solution Study Group. Demonstration of efficacy in the treatment of dry eye disease with 0.18% sodium hyaluronate ophthalmic solution (vismed, rejena). *American Journal of Ophthalmology* 2010 **149** 594–601. (<https://doi.org/10.1016/j.ajo.2009.09.023>)
- 73 Uddin JM & Davies PD. Treatment of upper eyelid retraction associated with thyroid eye disease with subconjunctival botulinum toxin injection. *Ophthalmology* 2002 **109** 1183–1187. ([https://doi.org/10.1016/s0161-6420\(02\)01041-2](https://doi.org/10.1016/s0161-6420(02)01041-2))
- 74 Marcocci C, Kahaly GJ, Krassas GE, Bartalena L, Prummel M, Stahl M, Altea MA, Nardi M, Pitz S, Boboridis K *et al.* Selenium and the course of mild Graves' orbitopathy. *New England Journal of Medicine* 2011 **364** 1920–1931. (<https://doi.org/10.1056/NEJMoa1012985>)
- 75 Negro R, Hegedus L, Attanasio R, Papini E & Winther KH. A 2018 European Thyroid Association survey on the use of selenium supplementation in Graves' hyperthyroidism and Graves' orbitopathy. *European Thyroid Journal* 2019 **8** 7–15. (<https://doi.org/10.1159/000494837>)
- 76 Kahaly GJ. Management of moderate-to-severe-GO. In *Graves' Orbitopathy*, pp. 140–171. Eds WM Wiersinga & GJ Kahaly. Karger, 2017.
- 77 Zang S & Kahaly GJ. Steroids and the immune response in Graves' orbitopathy. *Immunology, Endocrine and Metabolic Agents in Medicinal Chemistry* 2011 **11** 90–98. (<https://doi.org/10.2174/187152211795495689>)
- 78 Längericht J, Krämer I & Kahaly GJ. Glucocorticoids in Graves' orbitopathy: mechanisms of action and clinical application. *Therapeutic Advances in Endocrinology and Metabolism* 2020 **11** 2042018820958335. (<https://doi.org/10.1177/2042018820958335>)
- 79 Zang S, Ponto KA & Kahaly GJ. Clinical review: intravenous glucocorticoids for Graves' orbitopathy: efficacy and morbidity. *Journal of Clinical Endocrinology and Metabolism* 2011 **96** 320–332. (<https://doi.org/10.1210/jc.2010-1962>)
- 80 van Geest RJ, Sasim IV, Koppeschaar HP, Kalmann R, Stravers SN, Bijlsma WR & Mourits MP. Methylprednisolone pulse therapy for patients with moderately severe Graves' orbitopathy: a prospective, randomized, placebo-controlled study. *European Journal of Endocrinology* 2008 **158** 229–237. (<https://doi.org/10.1530/EJE-07-0558>)
- 81 Marcocci C, Bartalena L, Tanda ML, Manetti L, Dell'Unto E, Rocchi R, Barbesino G, Mazzi B, Bartolomei MP, Lepri P *et al.* Comparison of the effectiveness and tolerability of intravenous or oral glucocorticoids associated with orbital radiotherapy in the management of severe Graves' ophthalmopathy: results of a prospective, single-blind, randomized study. *Journal of Clinical Endocrinology and Metabolism* 2001 **86** 3562–3567. (<https://doi.org/10.1210/jcem.86.8.7737>)
- 82 Kahaly GJ, Pitz S, Hommel G & Dittmar M. Randomized, single blind trial of intravenous versus oral steroid monotherapy in Graves' orbitopathy. *Journal of Clinical Endocrinology and Metabolism* 2005 **90** 5234–5240. (<https://doi.org/10.1210/jc.2005-0148>)
- 83 Riedl M, Kolbe E, Kampmann E, Krämer I & Kahaly GJ. Prospectively recorded and MedDRA-coded safety data of intravenous methylprednisolone therapy in Graves' orbitopathy. *Journal of Endocrinological Investigation* 2015 **38** 177–182. (<https://doi.org/10.1007/s40618-014-0227-x>)

- 84 Hoppe E, Lee ACH, Hoppe D & Kahaly GJ. Predictive factors for changes in quality of life after steroid treatment for active moderate-to-severe Graves' orbitopathy: a prospective trial. *European Thyroid Journal* 2021 **9** 313–320. (<https://doi.org/10.1159/000508071>)
- 85 Bartalena L, Krassas GE, Wiersinga W, Marcocci C, Salvi M, Daumerie C, Bornaud C, Stahl M, Sassi L, Veronesi G *et al.* Efficacy and safety of three different cumulative doses of intravenous methylprednisolone for moderate to severe and active Graves' orbitopathy. *Journal of Clinical Endocrinology and Metabolism* 2012 **97** 4454–4463. (<https://doi.org/10.1210/jc.2012-2389>)
- 86 Zang S, Ponto KA, Pitz S & Kahaly GJ. Dose of intravenous steroids and therapy outcome in Graves' orbitopathy. *Journal of Endocrinological Investigation* 2011 **34** 876–880. (<https://doi.org/10.1007/BF03346732>)
- 87 Marcocci C, Watt T, Altea MA, Rasmussen AK, Feldt-Rasmussen U, Orgiazzi J, Bartalena L & European Group of Graves Orbitopathy. Fatal and non-fatal adverse events of glucocorticoid therapy for Graves' orbitopathy: a questionnaire survey among members of the European Thyroid Association. *European Journal of Endocrinology* 2012 **166** 247–253. (<https://doi.org/10.1530/EJE-11-0779>)
- 88 Curro N, Covelli D, Vannucchi G, Campi I, Pirola G, Simonetta S, Dazzi D, Guastella C, Pignataro L, Beck-Peccoz P *et al.* Therapeutic outcomes of high-dose intravenous steroids in the treatment of dysthyroid optic neuropathy. *Thyroid* 2014 **24** 897–905. (<https://doi.org/10.1089/thy.2013.0445>)
- 89 Sisti E, Coco B, Menconi F, Leo M, Rocchi R, Latrofa F, Profilo MA, Mazzi B, Vitti P, Marcocci C *et al.* Age and dose are major risk factors for liver damage associated with intravenous glucocorticoid pulse therapy for Graves' orbitopathy. *Thyroid* 2015 **25** 846–850. (<https://doi.org/10.1089/thy.2015.0061>)
- 90 Miskiewicz P, Jankowska A, Brodzinska K, Milczarek-Banach J & Ambroziak U. Influence of methylprednisolone pulse therapy on liver function in patients with Graves' orbitopathy. *International Journal of Endocrinology* 2018 **2018** 1978590. (<https://doi.org/10.1155/2018/1978590>)
- 91 Bartalena L, Veronesi G, Krassas GE, Wiersinga WM, Marcocci C, Marino M, Salvi M, Daumerie C, Bornaud C, Stahl M *et al.* Does early response to intravenous glucocorticoids predict the final outcome in patients with moderate-to-severe and active Graves' orbitopathy? *Journal of Endocrinological Investigation* 2017 **40** 547–553. (<https://doi.org/10.1007/s40618-017-0608-z>)
- 92 Wang Y, Sharma A, Padnick-Silver L, Francis-Sedlak M, Holt RJ, Foley C, Massry G & Douglas RS. Trends in treatment of active, moderate-to-severe thyroid eye disease in the United States. *Journal of the Endocrine Society* 2020 **4** bvaa140. (<https://doi.org/10.1210/jendso/bvaa140>)
- 93 Nedeljkovic Beleslin B, Ciric J, Stojkovic M, Savic S, Lalic T, Stojanovic M, Miletic M, Knezevic M, Stankovic B & Zarkovic M. Comparison of efficacy and safety of parenteral versus parenteral and oral glucocorticoid therapy in Graves' orbitopathy. *International Journal of Clinical Practice* 2020 **74** e13608. (<https://doi.org/10.1111/ijcp.13608>)
- 94 Marcocci C, Bartalena L, Panicucci M, Marconcini C, Cartei F, Cavallacci G, Laddaga M, Campobasso G, Baschieri L & Pinchera A. Orbital cobalt irradiation combined with retrobulbar or systemic corticosteroids for Graves' ophthalmopathy: a comparative study. *Clinical Endocrinology* 1987 **27** 33–42. (<https://doi.org/10.1111/j.1365-2265.1987.tb00836.x>)
- 95 Ebner R, Devoto MH, Weil D, Bordaberry M, Mir C, Martinez H, Bonelli L & Niepomniszcze H. Treatment of thyroid associated ophthalmopathy with periocular injections of triamcinolone. *British Journal of Ophthalmology* 2004 **88** 1380–1386. (<https://doi.org/10.1136/bjo.2004.046193>)
- 96 Lee SJ, Rim TH, Jang SY, Kim CY, Shin DY, Lee EJ, Lee SY & Yoon JS. Treatment of upper eyelid retraction related to thyroid-associated ophthalmopathy using subconjunctival triamcinolone injections. *Graefes' Archive for Clinical and Experimental Ophthalmology* 2013 **251** 261–270. (<https://doi.org/10.1007/s00417-012-2153-y>)
- 97 Gupta OP, Boynton JR, Sabini P, Markowitch Jr W & Quatela VC. Proptosis after retrobulbar corticosteroid injections. *Ophthalmology* 2003 **110** 443–447. ([https://doi.org/10.1016/S0161-6420\(02\)01743-8](https://doi.org/10.1016/S0161-6420(02)01743-8))
- 98 Huebert I, Heinicke N, Kook D, Boost KA, Miller CV, Mayer WJ, Haritoglou C, Kampik A, Gandorfer A, Hintschich C *et al.* Dual platelet inhibition in cases of severe retrobulbar hemorrhage following retrobulbar and peribulbar anesthesia. *Journal of Cataract and Refractive Surgery* 2015 **41** 2092–2101. (<https://doi.org/10.1016/j.jcrs.2015.10.051>)
- 99 Allison AC & Eugui EM. Mycophenolate mofetil and its mechanisms of action. *Immunopharmacology* 2000 **47** 85–118. ([https://doi.org/10.1016/S0162-3109\(00\)00188-0](https://doi.org/10.1016/S0162-3109(00)00188-0))
- 100 Staatz CE & Tett SE. Pharmacology and toxicology of mycophenolate in organ transplant recipients: an update. *Archives of Toxicology* 2014 **88** 1351–1389. (<https://doi.org/10.1007/s00204-014-1247-1>)
- 101 Azzola A, Havryk A, Chhajed P, Hostettler K, Black J, Johnson P, Roth M, Glanville A & Tamm M. Everolimus and mycophenolate mofetil are potent inhibitors of fibroblast proliferation after lung transplantation. *Transplantation* 2004 **77** 275–280. (<https://doi.org/10.1097/01.TP0000101822.50960.AB>)
- 102 Roos N, Poulalhon N, Farge D, Madelaine I, Mauviel A & Verrecchia F. In vitro evidence for a direct antifibrotic role of the immunosuppressive drug mycophenolate mofetil. *Journal of Pharmacology and Experimental Therapeutics* 2007 **321** 583–589. (<https://doi.org/10.1124/jpet.106.117051>)
- 103 Petrova DT, Brandhorst G, Brehmer F, Gross O, Oellerich M & Armstrong VW. Mycophenolic acid displays IMPDH-dependent and IMPDH-independent effects on renal fibroblast proliferation and function. *Therapeutic Drug Monitoring* 2010 **32** 405–412. (<https://doi.org/10.1097/FTD.0b013e3181e44260>)
- 104 Zhang L, Grennan-Jones F, Draman MS, Lane C, Morris D, Dayan CM, Tee AR & Ludgate M. Possible targets for nonimmunosuppressive therapy of Graves' orbitopathy. *Journal of Clinical Endocrinology and Metabolism* 2014 **99** E1183–E1190. (<https://doi.org/10.1210/jc.2013-4182>)
- 105 Gabardi S, Tran JL & Clark MR. Enteric-coated mycophenolate sodium. *Annals of Pharmacotherapy* 2003 **37** 1685–1693. (<https://doi.org/10.1345/aph.1D063>)
- 106 Gardiner KM, Tett SE & Staatz CE. Is conversion from mycophenolate mofetil to enteric-coated mycophenolate sodium justifiable for gastrointestinal quality of life? *Drugs in R&D* 2018 **18** 271–282. (<https://doi.org/10.1007/s40268-018-0254-8>)
- 107 Ye X, Bo X, Hu X, Cui H, Lu B, Shao J & Wang J. Efficacy and safety of mycophenolate mofetil in patients with active moderate-to-severe Graves' orbitopathy. *Clinical Endocrinology* 2017 **86** 247–255. (<https://doi.org/10.1111/cen.13170>)
- 108 Kahaly GJ, Riedl M, König J, Pitz S, Ponto K, Diana T, Kampmann E, Kolbe E, Eckstein A, Moeller LC *et al.* Mycophenolate plus methylprednisolone versus methylprednisolone alone in active, moderate-to-severe Graves' orbitopathy (MINGO): a randomised, observer-masked, multicentre trial. *Lancet: Diabetes and Endocrinology* 2018 **6** 287–298. ([https://doi.org/10.1016/S2213-8587\(18\)30020-2](https://doi.org/10.1016/S2213-8587(18)30020-2))
- 109 Orgiazzi J. Adding the immunosuppressant mycophenolate mofetil to medium-dose infusions of methylprednisolone improves the treatment of Graves' orbitopathy. *Clinical Thyroidology* 2018 **30** 10–14. (<https://doi.org/10.1089/ct.2018;30.10-14>)
- 110 Lee ACH, Riedl M, Frommer L, Diana T & Kahaly GJ. Systemic safety analysis of mycophenolate in Graves' orbitopathy. *Journal of Endocrinological Investigation* 2020 **43** 767–777. (<https://doi.org/10.1007/s40618-019-01161-z>)
- 111 Riedl M, Kuhn A, Krämer I, Kolbe E & Kahaly GJ. Prospective, systematically recorded mycophenolate safety data in Graves' orbitopathy. *Journal of Endocrinological Investigation* 2016 **39** 687–694. (<https://doi.org/10.1007/s40618-016-0441-9>)

- 112 Quah Qin Xian N, Alnahrawy A, Akshikar R & Lee V. Real-world efficacy and safety of mycophenolate mofetil in active moderate-to-sight-threatening thyroid eye disease. *Clinical Ophthalmology* 2021 **15** 1921–1932. (<https://doi.org/10.2147/OPTH.S305717>)
- 113 Mourits MP, van Kempen-Harteveld ML, Garcia MB, Koppeschaar HP, Tick L & Terwee CB. Radiotherapy for Graves' orbitopathy: randomised placebo-controlled study. *Lancet* 2000 **355** 1505–1509. ([https://doi.org/10.1016/S0140-6736\(00\)02165-6](https://doi.org/10.1016/S0140-6736(00)02165-6))
- 114 Prummel MF, Terwee CB, Gerding MN, Baldeschi L, Mourits MP, Blank L, Dekker FW & Wiersinga WM. A randomized controlled trial of orbital radiotherapy versus sham irradiation in patients with mild Graves' ophthalmopathy. *Journal of Clinical Endocrinology and Metabolism* 2004 **89** 15–20. (<https://doi.org/10.1210/jc.2003-030809>)
- 115 Gorman CA, Garrity JA, Fatourech V, Bahn RS, Petersen IA, Stafford SL, Earle JD, Forbes GS, Kline RW, Bergstralh EJ *et al.* A prospective, randomized, double-blind, placebo-controlled study of orbital radiotherapy for Graves' ophthalmopathy. *Ophthalmology* 2001 **108** 1523–1534. ([https://doi.org/10.1016/S0161-6420\(01\)00632-7](https://doi.org/10.1016/S0161-6420(01)00632-7))
- 116 Rajendram R, Taylor PN, Wilson VJ, Harris N, Morris OC, Tomlinson M, Yarrow S, Garrett H, Herbert HM, Dick AD *et al.* Combined immunosuppression and radiotherapy in thyroid eye disease (CIRTED): a multicentre, 2 x 2 factorial, double-blind, randomised controlled trial. *Lancet: Diabetes and Endocrinology* 2018 **6** 299–309. ([https://doi.org/10.1016/S2213-8587\(18\)30021-4](https://doi.org/10.1016/S2213-8587(18)30021-4))
- 117 Prummel MF, Mourits MP, Blank L, Berghout A, Koornneef L & Wiersinga WM. Randomized double-blind trial of prednisone versus radiotherapy in Graves' ophthalmopathy. *Lancet* 1993 **342** 949–954. ([https://doi.org/10.1016/0140-6736\(93\)92001-a](https://doi.org/10.1016/0140-6736(93)92001-a))
- 118 Marcocci C, Bartalena L, Bogazzi F, Bruno-Bossio G, Lepri A & Pinchera A. Orbital radiotherapy combined with high dose systemic glucocorticoids for Graves' ophthalmopathy is more effective than radiotherapy alone: results of a prospective randomized study. *Journal of Endocrinological Investigation* 1991 **14** 853–860. (<https://doi.org/10.1007/BF03347943>)
- 119 Bartalena L, Marcocci C, Chiovato L, Laddaga M, Lepri G, Andreani D, Cavallacci G, Baschieri L & Pinchera A. Orbital cobalt irradiation combined with systemic corticosteroids for Graves' ophthalmopathy: comparison with systemic corticosteroids alone. *Journal of Clinical Endocrinology and Metabolism* 1983 **56** 1139–1144. (<https://doi.org/10.1210/jcem-56-6-1139>)
- 120 Kim JW, Han SH, Son BJ, Rim TH, Keum KC & Yoon JS. Efficacy of combined orbital radiation and systemic steroids in the management of Graves' orbitopathy. *Graefes Archive for Clinical and Experimental Ophthalmology* 2016 **254** 991–998. (<https://doi.org/10.1007/s00417-016-3280-7>)
- 121 Oeverhaus M, Witteler T, Lax H, Esser J, Fuhrer D & Eckstein A. Combination therapy of intravenous steroids and orbital irradiation is more effective than intravenous steroids alone in patients with Graves' orbitopathy. *Hormone and Metabolic Research* 2017 **49** 739–747. (<https://doi.org/10.1055/s-0043-116945>)
- 122 Tanda ML & Bartalena L. Efficacy and safety of orbital radiotherapy for Graves' orbitopathy. *Journal of Clinical Endocrinology and Metabolism* 2012 **97** 3857–3865. (<https://doi.org/10.1210/jc.2012-2758>)
- 123 Kahaly GJ, Rösler HP, Pitz S & Hommel G. Low- versus high-dose radiotherapy for Graves' ophthalmopathy: a randomized, single blind trial. *Journal of Clinical Endocrinology and Metabolism* 2000 **85** 102–108. (<https://doi.org/10.1210/jcem.85.1.6257>)
- 124 Marquez SD, Lum BL, McDougall IR, Katkuri S, Levin PS, MacManus M & Donaldson SS. Long-term results of irradiation for patients with progressive Graves' ophthalmopathy. *International Journal of Radiation Oncology, Biology, Physics* 2001 **51** 766–774. ([https://doi.org/10.1016/S0360-3016\(01\)01699-6](https://doi.org/10.1016/S0360-3016(01)01699-6))
- 125 Marcocci C, Bartalena L, Rocchi R, Marino M, Menconi F, Morabito E, Mazzi B, Mazzeo S, Sartini MS, Nardi M *et al.* Long-term safety of orbital radiotherapy for Graves' ophthalmopathy. *Journal of Clinical Endocrinology and Metabolism* 2003 **88** 3561–3566. (<https://doi.org/10.1210/jc.2003-030260>)
- 126 Wakelkamp IM, Tan H, Saeed P, Schlingemann RO, Verbraak FD, Blank LE, Prummel MF & Wiersinga WM. Orbital irradiation for Graves' ophthalmopathy: is it safe? A long-term follow-up study. *Ophthalmology* 2004 **111** 1557–1562. (<https://doi.org/10.1016/j.optha.2003.12.054>)
- 127 Godfrey KJ & Kazim M. Radiotherapy for active thyroid eye disease. *Ophthalmic Plastic and Reconstructive Surgery* 2018 **34** (4S Supplement 1) S98–S104. (<https://doi.org/10.1097/IOP.0000000000001074>)
- 128 Christiansen E & Kofoed-Enevoldsen A. Radiotherapy for Graves' ophthalmopathy. *Journal of Clinical Endocrinology and Metabolism* 2001 **86** 2327–2328 (Letter). (<https://doi.org/10.1210/jcem.86.5.7507-1>)
- 129 Kahaly G, Schrezenmeier J, Krause U, Schweikert B, Meuer S, Müller W, Dennebaum R & Beyer J. Cyclosporin and prednisone v. prednisone in treatment of Graves' ophthalmopathy: a controlled, randomized and prospective study. *European Journal of Clinical Investigation* 1986 **16** 415–422. (<https://doi.org/10.1111/j.1365-2362.1986.tb01016.x>)
- 130 Prummel MF, Mourits MP, Berghout A, Krenning EP, van der Gaag R, Koornneef L & Wiersinga WM. Prednisone and cyclosporine in the treatment of severe Graves' ophthalmopathy. *New England Journal of Medicine* 1989 **321** 1353–1359. (<https://doi.org/10.1056/NEJM19891163212002>)
- 131 Perros P, Weightman DR, Crombie AL & Kendall-Taylor P. Azathioprine in the treatment of thyroid-associated ophthalmopathy. *Acta Endocrinologica* 1990 **122** 8–12. (<https://doi.org/10.1530/acta.0.1220008>)
- 132 Chalvatzis NT, Tzamalīs AK, Kalantzis GK, El-Hindy N, Dimitrakos SA & Potts MJ. Safety and efficacy of combined immunosuppression and orbital radiotherapy in thyroid-related restrictive myopathy: two-center experience. *European Journal of Ophthalmology* 2014 **24** 953–959. (<https://doi.org/10.5301/ejo.5000463>)
- 133 Tsui S, Naik V, Hoa N, Hwang CJ, Afifyan NF, Sinha Hikim A, Gianoukakis AG, Douglas RS & Smith TJ. Evidence for an association between thyroid-stimulating hormone and insulin-like growth factor 1 receptors: a tale of two antigens implicated in Graves' disease. *Journal of Immunology* 2008 **181** 4397–4405. (<https://doi.org/10.4049/jimmunol.181.6.4397>)
- 134 Douglas RS, Naik V, Hwang CJ, Afifyan NF, Gianoukakis AG, Sand D, Kamat S & Smith TJ. B cells from patients with Graves' disease aberrantly express the IGF-1 receptor: implications for disease pathogenesis. *Journal of Immunology* 2008 **181** 5768–5774. (<https://doi.org/10.4049/jimmunol.181.8.5768>)
- 135 Smith TJ & Janssen JAMJL. Insulin-like growth factor-I receptor and thyroid-associated ophthalmopathy. *Endocrine Reviews* 2019 **40** 236–267. (<https://doi.org/10.1210/er.2018-00066>)
- 136 Smith TJ, Kahaly GJ, Ezra DG, Fleming JC, Dailey RA, Tang RA, Harris GJ, Antonelli A, Salvi M, Goldberg RA *et al.* Teprotumumab for thyroid-associated ophthalmopathy. *New England Journal of Medicine* 2017 **376** 1748–1761. (<https://doi.org/10.1056/NEJMoa1614949>)
- 137 Douglas RS, Kahaly GJ, Patel A, Sile S, Thompson EH, Perdok R, Fleming JC, Fowler BT, Marcocci C, Marino M *et al.* Teprotumumab for the treatment of active thyroid eye disease. *New England Journal of Medicine* 2020 **382** 341–352. (<https://doi.org/10.1056/NEJMoa1910434>)
- 138 Kahaly GJ, Douglas RS, Holt RJ, Sile S & Smith TJ. Teprotumumab for patients with active thyroid eye disease: a pooled data analysis, subgroup analyses, and off-treatment follow-up results from two randomised, double-masked, placebo-controlled, multicentre trials. *Lancet: Diabetes and Endocrinology* 2021 **9** 360–372. ([https://doi.org/10.1016/S2213-8587\(21\)00056-5](https://doi.org/10.1016/S2213-8587(21)00056-5))
- 139 Hoang TD, Nguyen NT, Chou E & Shakir MK. Rapidly progressive cognitive decline associated with teprotumumab in thyroid eye disease. *BMJ Case Reports* 2021 **14** e242153. (<https://doi.org/10.1136/bcr-2021-242153>)

- 140 Winn BJ & Kersten RC. Teprotumumab: interpreting the clinical trials in the context of thyroid eye disease pathogenesis and current therapies. *Ophthalmology* 2021 In press. (<https://doi.org/10.1016/j.ophtha.2021.04.024>)
- 141 Salvi M, Vannucchi G, Campi I, Curro N, Dazzi D, Simonetta S, Bonara P, Rossi S, Sina C, Guastella C *et al.* Treatment of Graves' disease and associated ophthalmopathy with the anti-CD20 monoclonal antibody rituximab: an open study. *European Journal of Endocrinology* 2007 **156** 33–40. (<https://doi.org/10.1530/eje.1.02325>)
- 142 Mitchell AL, Gan EH, Morris M, Johnson K, Neoh C, Dickinson AJ, Perros P & Pearce SH. The effect of B cell depletion therapy on anti-TSH receptor antibodies and clinical outcome in glucocorticoid-refractory Graves' orbitopathy. *Clinical Endocrinology* 2013 **79** 437–442. (<https://doi.org/10.1111/cen.12141>)
- 143 Khanna D, Chong KK, Afifyan NF, Hwang CJ, Lee DK, Garneau HC, Goldberg RA, Darwin CH, Smith TJ & Douglas RS. Rituximab treatment of patients with severe, corticosteroid-resistant thyroid-associated ophthalmopathy. *Ophthalmology* 2010 **117** 133–139.e2. (<https://doi.org/10.1016/j.ophtha.2009.05.029>)
- 144 Stan MN, Garrity JA, Carranza Leon BG, Prabin T, Bradley EA & Bahn RS. Randomized controlled trial of rituximab in patients with Graves' orbitopathy. *Journal of Clinical Endocrinology and Metabolism* 2015 **100** 432–441. (<https://doi.org/10.1210/jc.2014-2572>)
- 145 Salvi M, Vannucchi G, Curro N, Campi I, Covelli D, Dazzi D, Simonetta S, Guastella C, Pignataro L, Avignone S *et al.* Efficacy of B-cell targeted therapy with rituximab in patients with active moderate to severe Graves' orbitopathy: a randomized controlled study. *Journal of Clinical Endocrinology and Metabolism* 2015 **100** 422–431. (<https://doi.org/10.1210/jc.2014-3014>)
- 146 Vannucchi G, Campi I, Covelli D, Curro N, Lazzaroni E, Palomba A, Soranna D, Zambon A, Fugazzola L, Muller I *et al.* Efficacy profile and safety implications of very low dose rituximab in patients with Graves' orbitopathy. *Thyroid* 2020 **31** 821–828. (<https://doi.org/10.1089/thy.2020.0269>)
- 147 Hamed Azzam S, Kang S, Salvi M & Ezra DG. Tocilizumab for thyroid eye disease. *Cochrane Database of Systematic Reviews* 2018 **11** CD012984. (<https://doi.org/10.1002/14651858.CD012984.pub2>)
- 148 Perez-Moreiras JV, Gomez-Reino JJ, Maneiro JR, Perez-Pampin E, Romo Lopez A, Rodriguez Alvarez FM, Castillo Laguarda JM, Del Estad Cabello A, Gessa Sorroche M, Espana Gregori E *et al.* Efficacy of tocilizumab in patients with moderate-to-severe corticosteroid-resistant Graves orbitopathy: a randomized clinical trial. *American Journal of Ophthalmology* 2018 **195** 181–190. (<https://doi.org/10.1016/j.ajo.2018.07.038>)
- 149 Sanchez-Bilbao L, Martinez-Lopez D, Revenga M, Lopez-Vazquez A, Valls-Pascual E, Atienza-Mateo B, Valls-Espinosa B, Maiz-Alonso O, Blanco A, Torre-Salaberri I *et al.* Anti-IL-6 receptor tocilizumab in refractory Graves' orbitopathy: national multicenter observational study of 48 patients. *Journal of Clinical Medicine* 2020 **9** 2816. (<https://doi.org/10.3390/jcm9092816>)
- 150 Jose C-MJ, Rivera-Moscoso R, Jorge F-RA, Vargas-Sanchez J, Ortega-Gutierrez G, Madriz-Prado R, Velasco-Ramos PC, Munoz-Monroy OE *et al.* Tocilizumab in glucocorticoid-resistant Graves orbitopathy. A case series report of a Mexican population. *Annales d'Endocrinologie* 2020 **81** 78–82. (<https://doi.org/10.1016/j.ando.2020.01.003>)
- 151 Perez-Moreiras JV, Varela-Agra M, Prada-Sanchez MC & Prada-Ramallal G. Steroid-resistant Graves' orbitopathy treated with tocilizumab in real-world clinical practice: a 9-year single-center experience. *Journal of Clinical Medicine* 2021 **10** 706. (<https://doi.org/10.3390/jcm10040706>)
- 152 Kazatchkine MD & Kaveri SV. Immunomodulation of autoimmune and inflammatory diseases with intravenous immune globulin. *New England Journal of Medicine* 2001 **345** 747–755. (<https://doi.org/10.1056/NEJMra993360>)
- 153 Kahaly G, Pitz S, Müller-Forell W & Hommel G. Randomized trial of intravenous immunoglobulins versus prednisolone in Graves' ophthalmopathy. *Clinical and Experimental Immunology* 1996 **106** 197–202. (<https://doi.org/10.1046/j.1365-2249.1996.d01-854.x>)
- 154 Kahaly G, Lieb W, Muller-Forell W, Mainberger M, Beyer J, Vollmar J & Staiger C. Ciamezone in endocrine orbitopathy. A randomized double-blind, placebo-controlled study. *Acta Endocrinologica* 1990 **122** 13–21. (<https://doi.org/10.1530/acta.0.1220013>)
- 155 Dickinson AJ, Vaidya B, Miller M, Coulthard A, Perros P, Baister E, Andrews CD, Hesse L, Heverhagen JT, Heufelder AE *et al.* Double-blind, placebo-controlled trial of octreotide long-acting repeatable (LAR) in thyroid-associated ophthalmopathy. *Journal of Clinical Endocrinology and Metabolism* 2004 **89** 5910–5915. (<https://doi.org/10.1210/jc.2004-0697>)
- 156 Wemeau JL, Caron P, Beckers A, Rohmer V, Orgiazzi J, Borson-Chazot F, Nocaudie M, Perimenis P, Bisot-Locard S, Bourdeix I *et al.* Octreotide (long-acting release formulation) treatment in patients with Graves' orbitopathy: clinical results of a four-month, randomized, placebo-controlled, double-blind study. *Journal of Clinical Endocrinology and Metabolism* 2005 **90** 841–848. (<https://doi.org/10.1210/jc.2004-1334>)
- 157 Stan MN, Garrity JA, Bradley EA, Woog JJ, Bahn MM, Brennan MD, Bryant SC, Achenbach SJ & Bahn RS. Randomized, double-blind, placebo-controlled trial of long-acting release octreotide for treatment of Graves' ophthalmopathy. *Journal of Clinical Endocrinology and Metabolism* 2006 **91** 4817–4824. (<https://doi.org/10.1210/jc.2006-1105>)
- 158 Chang TC & Liao SL. Slow-release lanreotide in Graves' ophthalmopathy: a double-blind randomized, placebo-controlled clinical trial. *Journal of Endocrinological Investigation* 2006 **29** 413–422. (<https://doi.org/10.1007/BF03344124>)
- 159 Wakelkamp IM, Gerding MN, Van Der Meer JW, Prummel MF & Wiersinga WM. Both Th1- and Th2-derived cytokines in serum are elevated in Graves' ophthalmopathy. *Clinical and Experimental Immunology* 2000 **121** 453–457. (<https://doi.org/10.1046/j.1365-2249.2000.01335.x>)
- 160 Kishazi E, Dor M, Eperon S, Oberic A, Turck N & Hamedani M. Differential profiling of lacrimal cytokines in patients suffering from thyroid-associated orbitopathy. *Scientific Reports* 2018 **8** 10792. (<https://doi.org/10.1038/s41598-018-29113-2>)
- 161 Durrani OM, Reuser TQ & Murray PI. Infliximab: a novel treatment for sight-threatening thyroid associated ophthalmopathy. *Orbit* 2005 **24** 117–119. (<https://doi.org/10.1080/01676830590912562>)
- 162 Paridaens D, van den Bosch WA, van der Loos TL, Krenning EP & van Hagen PM. The effect of etanercept on Graves' ophthalmopathy: a pilot study. *Eye* 2005 **19** 1286–1289. (<https://doi.org/10.1038/sj.eye.6701768>)
- 163 Ayabe R, Rootman DB, Hwang CJ, Ben-Artzi A & Goldberg R. Adalimumab as steroid-sparing treatment of inflammatory-stage thyroid eye disease. *Ophthalmic Plastic and Reconstructive Surgery* 2014 **30** 415–419. (<https://doi.org/10.1097/IOP.0000000000000211>)
- 164 Sipkova Z, Insull EA, David J, Turner HE, Keren S & Norris JH. Early use of steroid-sparing agents in the inactivation of moderate-to-severe active thyroid eye disease: a step-down approach. *Clinical Endocrinology* 2018 **89** 834–839. (<https://doi.org/10.1111/cen.13834>)
- 165 Wakelkamp IM, Baldeschi L, Saeed P, Mourits MP, Prummel MF & Wiersinga WM. Surgical or medical decompression as a first-line treatment of optic neuropathy in Graves' ophthalmopathy? A randomized controlled trial. *Clinical Endocrinology* 2005 **63** 323–328. (<https://doi.org/10.1111/j.1365-2265.2005.02345.x>)
- 166 Baldeschi L. Rehabilitative surgery. In *Graves' Orbitopathy A Multidisciplinary Approach – Questions and Answers*, 3rd ed. Eds WM Wiersinga & GJ Kahaly. Basel, Switzerland: Karger, 2017.
- 167 Kahaly GJ, Bartalena L, Hegedus L, Leenhardt L, Poppe K & Pearce SH. European Thyroid Association guideline for the management of Graves' hyperthyroidism. *European Thyroid Journal* 2018 **7** 167–186. (<https://doi.org/10.1159/000490384>)
- 168 Marcocci C, Bruno-Bossio G, Manetti L, Tanda ML, Miccoli P, Iacconi P, Bartolomei MP, Nardi M, Pinchera A & Bartalena L. The course of Graves' ophthalmopathy is not influenced by near total



- thyroidectomy: a case-control study. *Clinical Endocrinology* 1999 **51** 503–508. (<https://doi.org/10.1046/j.1365-2265.1999.00843.x>)
- 169 Laurberg P, Wallin G, Tallstedt L, Abraham-Nordling M, Lundell G & Torring O. TSH-receptor autoimmunity in Graves' disease after therapy with anti-thyroid drugs, surgery, or radioiodine: a 5-year prospective randomized study. *European Journal of Endocrinology* 2008 **158** 69–75. (<https://doi.org/10.1530/EJE-07-0450>)
- 170 Diana T, Ponto KA & Kahaly GJ. Thyrotropin receptor antibodies and Graves' orbitopathy. *Journal of Endocrinological Investigation* 2021 **44** 703–712. (<https://doi.org/10.1007/s40618-020-01380-9>)
- 171 Zarkovic M, Wiersinga W, Perros P, Bartalena L, Donati S, Okosieme O, Morris D, Fichter N, Lareida J, Daumerie C *et al.* Antithyroid drugs in Graves' hyperthyroidism: differences between 'block and replace' and 'titration' regimes in frequency of euthyroidism and Graves' orbitopathy during treatment. *Journal of Endocrinological Investigation* 2021 **44** 371–378. (<https://doi.org/10.1007/s40618-020-01320-7>)
- 172 Erdogan MF, Demir Ö, Ersoy RÜ, Gul K, Aydogan Bİ, Uc ZA, Mete T, Ertek S, Unluturk U, Cakir B *et al.* Comparison of early total thyroidectomy with antithyroid treatment in patients with moderate-severe Graves' orbitopathy: a randomized prospective trial. *European Thyroid Journal* 2016 **5** 106–111. (<https://doi.org/10.1159/000444796>)
- 173 Meyer Zu Horste M, Pateronis K, Walz MK, Alesina P, Mann K, Schott M, Esser J & Eckstein AK. The effect of early thyroidectomy on the course of active Graves' orbitopathy (GO): a retrospective case study. *Hormone and Metabolic Research* 2016 **48** 433–439. (<https://doi.org/10.1055/s-0042-108855>)
- 174 Menconi F, Marino M, Pinchera A, Rocchi R, Mazzi B, Nardi M, Bartalena L & Marcocci C. Effects of total thyroid ablation versus near-total thyroidectomy alone on mild to moderate Graves' orbitopathy treated with intravenous glucocorticoids. *Journal of Clinical Endocrinology and Metabolism* 2007 **92** 1653–1658. (<https://doi.org/10.1210/jc.2006-1800>)
- 175 Moleti M, Violi MA, Montanini D, Trombetta C, Di Bella B, Sturniolo G, Presti S, Alibrandi A, Campenni A, Baldari S *et al.* Radioiodine ablation of postsurgical thyroid remnants after treatment with recombinant human TSH (rhTSH) in patients with moderate-to-severe Graves' orbitopathy (GO): a prospective, randomized, single-blind clinical trial. *Journal of Clinical Endocrinology and Metabolism* 2014 **99** 1783–1789. (<https://doi.org/10.1210/jc.2013-3093>)
- 176 Leo M, Marcocci C, Pinchera A, Nardi M, Megna L, Rocchi R, Latrofa F, Altea MA, Mazzi B, Sisti E *et al.* Outcome of Graves' orbitopathy after total thyroid ablation and glucocorticoid treatment: follow-up of a randomized clinical trial. *Journal of Clinical Endocrinology and Metabolism* 2012 **97** E44–E48. (<https://doi.org/10.1210/jc.2011-2077>)
- 177 Bartalena L, Macchia PE, Marcocci C, Salvi M & Vermiglio F. Effects of treatment modalities for Graves' hyperthyroidism on Graves' orbitopathy: a 2015 Italian Society of Endocrinology Consensus Statement. *Journal of Endocrinological Investigation* 2015 **38** 481–487. (<https://doi.org/10.1007/s40618-015-0257-z>)
- 178 Elbers L, Mourits M & Wiersinga W. Outcome of very long-term treatment with antithyroid drugs in Graves' hyperthyroidism associated with Graves' orbitopathy. *Thyroid* 2011 **21** 279–283. (<https://doi.org/10.1089/thy.2010.0181>)
- 179 Laurberg P, Berman DC, Andersen S & Bulow Pedersen I. Sustained control of Graves' hyperthyroidism during long-term low-dose antithyroid drug therapy of patients with severe Graves' orbitopathy. *Thyroid* 2011 **21** 951–956. (<https://doi.org/10.1089/thy.2011.0039>)
- 180 Bartalena L, Chiovato L, Marcocci C, Vitti P, Piantanida E & Tanda ML. Management of Graves' hyperthyroidism and orbitopathy in time of COVID-19 pandemic. *Journal of Endocrinological Investigation* 2020 **43** 1149–1151. (<https://doi.org/10.1007/s40618-020-01293-7>)
- 181 Puig-Domingo M, Marazuela M & Giustina A. COVID-19 and endocrine diseases. A statement from the European Society of Endocrinology. *Endocrine* 2020 **68** 2–5. (<https://doi.org/10.1007/s12020-020-02294-5>)
- 182 WHO Rapid Evidence Appraisal for COVID-19 Therapies (REACT) Working Group, Sterne JAC, Murthy S, Diaz JV, Slutsky AS, Villar J, Angus DC, Annane D, Azevedo LCP, Berwanger O *et al.* Association between administration of systemic corticosteroids and mortality among critically ill patients with COVID-19: a meta-analysis. *JAMA* 2020 **324** 1330–1341. (<https://doi.org/10.1001/jama.2020.17023>)
- 183 Alexaki VI & Henneicke H. The role of glucocorticoids in the management of COVID-19. *Hormone and Metabolic Research* 2021 **53** 9–15. (<https://doi.org/10.1055/a-1300-2550>)
- 184 Clarke SA, Phylactou M, Patel B, Mills EG, Muzi B, Izzi-Engbeaya C, Choudhury S, Khoo B, Meeran K, Comminos AN *et al.* Normal adrenal and thyroid function in patients who survive COVID-19 infection. *Journal of Clinical Endocrinology and Metabolism* 2021 **106** 2208–2220. (<https://doi.org/10.1210/clinem/dgab349>)
- 185 Jespersen S, Nygaard B & Kristensen LØ. Methylprednisolone pulse treatment of Graves' ophthalmopathy is not associated with secondary adrenocortical insufficiency. *European Thyroid Journal* 2015 **4** 222–225. (<https://doi.org/10.1159/000440834>)
- 186 Ambroziak U, Bluszcz G, Bednarczuk T & Miskiewicz P. The influence of Graves' orbitopathy treatment with intravenous glucocorticoids on adrenal function. *Endokrynologia Polska* 2017 **68** 430–433. (<https://doi.org/10.5603/EPa.2017.0036>)
- 187 Neumann S, Krieger CC & Gershengorn MC. Targeting TSH and IGF-1 receptors to treat thyroid eye disease. *European Thyroid Journal* 2020 **9** (Supplement 1) 59–65. (<https://doi.org/10.1159/000511538>)
- 188 Krause G, Eckstein A & Schulein R. Modulating TSH receptor signaling for therapeutic benefit. *European Thyroid Journal* 2020 **9** (Supplement 1) 66–77. (<https://doi.org/10.1159/000511871>)
- 189 Lee ACH & Kahaly GJ. Novel approaches for immunosuppression in Graves' hyperthyroidism and associated orbitopathy. *European Thyroid Journal* 2020 **9** (Supplement 1) 17–30. (<https://doi.org/10.1159/000508789>)
- 190 Roos JCP & Murthy R. Sirolimus (rapamycin) for the targeted treatment of the fibrotic sequelae of Graves' orbitopathy. *Eye* 2019 **33** 679–682. (<https://doi.org/10.1038/s41433-019-0340-3>)
- 191 Masetti G & Ludgate M. Microbiome and Graves' orbitopathy. *European Thyroid Journal* 2020 **9** (Supplement 1) 78–85. (<https://doi.org/10.1159/000512255>)

Received 6 May 2021

Revised version received 30 June 2021

Accepted 23 July 2021